

Assessment and Grading of Pulmonary Regurgitation Following Tetralogy of Fallot Surgical Repair by Cardiac Magnetic Resonance Imaging

MOHAMED S. AYYAD, M.Sc.; MAGDY M. EL RAKHAWY, M.D. and ZAINAB A. RAMADAN, M.D.

The Department of Diagnostic and Interventional Radiology, Faculty of Medicine, Mansoura University

Abstract

Background: Pulmonary regurgitation (PR) is a common complication following tetralogy of Fallot (TOF) surgical repair. It may lead to right ventricular dilatation and deterioration of right ventricular function. The degree of PR impacts the pulmonary valve replacement (PVR) decision.

As echocardiography remains the primary investigation for the assessment of PR, cardiac magnetic resonance (CMR) has been established as the investigation of choice for the accurate quantitative assessment of the degree of PR.

Aim of Study: This study aimed to comprehensively assess the role of CMR in the evaluation and grading of PR. It also aimed to assess the role of CMR in the evaluation of the RV size and function which are affected as a consequence of PR.

Material and Methods: This prospective study included 36 operated TOF patients. They were evaluated for degree of PR, RV volumes, and function by CMR after performing echocardiography.

Results: In this prospective study, regurgitant volume and fraction were calculated for all cases via phase-contrast MRI. PR was assessed for all cases with 2-dimensional (2D) echocardiography apart from one case that could not be assessed. CMR was able to accurately assess and grade PR. A statistically significant difference (p -value=0.009) was observed when comparing the results of both modalities for moderate PR. No statistically significant difference could be observed between both modalities regarding mild (p -value=0.11) and severe PR (p -value=0.381) categories. 11 cases had impaired RV function, 8 of which had severe PR.

Conclusions: Both cardiac magnetic resonance and echocardiography are able to accurately assess and grade pulmonary regurgitation following tetralogy of Fallot surgical repair. There was a statistically significant difference between CMR and echocardiography regarding the moderate category of pulmonary

regurgitation. There was a positive correlation between the severity of PR and impairment of RV function.

Key Words: TOF – Cardiac MRI – Echocardiography – PR.

Introduction

TETRALOGY of Fallot is a complex congenital cardiac pathology characterized by four main components: Stenosis of the right ventricular outflow tract (RVOT), hypertrophy of the RV, overriding of the aorta, and ventricular septal defect [1].

Pulmonary regurgitation following TOF repair is common with over 80% of the cases having moderate to severe regurgitation. PR is caused by the use of a trans-annular patch during RVOT reconstruction and exaggerated infundibulectomy involving the pulmonary valve annulus. Long-term follow-up has

List of Abbreviations:

CMR	: Cardiac magnetic resonance.
PR	: Pulmonary regurgitation.
TOF	: Tetralogy of Fallot.
PVR	: Pulmonary valve replacement.
RV	: Right ventricle.
2D	: 2-dimensional.
RVOT	: Right ventricular outflow tract.
SSFP	: Steady state free precession.
SD	: Standard deviation.
EDV	: End-diastolic volume.
EDVI	: End-diastolic volume index.
MPA	: Main pulmonary artery.
RPA	: Right pulmonary artery.
LPA	: Left pulmonary artery.
MHZ	: Megahertz.
DICOM	: Digital imaging and communication in medicine.
EF	: Ejection fraction.
TAPSE	: Tricuspid annular plane systolic excursion.
EDD	: End-diastolic dimensions.
TR	: Time of repetition.
TE	: Time of echo.
FOV	: Field of view.
4CH	: Four chamber.

Correspondence to: Dr. Mohamed S. Ayyad,
E-Mail: Mohamed_ayyad_93@std.mans.edu.eg
M.ayyad9333@gmail.com

shown that PR can lead to significant disability in the form of progressive right ventricular dilatation, deterioration of RV function, and arrhythmia. When the grade of PR is questionable, CMR is the reference technique for accurate quantification of the regurgitant fraction via phase contrast imaging [2].

Chronic PR can result in right ventricular dilatation [3]. Pulmonary valve replacement (PVR) may be necessary to prevent or resolve this complication [3,4].

Right ventricular dysfunction may occur as a serious complication of long-term PR in patients with complete repair of TOF with high morbidity and mortality rates [5].

Cardiac magnetic resonance is most convenient for follow-up of cases following TOF repair as it is not associated with exposure to ionizing radiation and is non-invasive. It provides valuable quantitative data regarding the biventricular size and function. It also gives information about blood flow measurements, myocardial viability, and cardiovascular anatomy [6].

Traditional “black-blood” techniques, such as turbo or fast spin sequences allow the assessment of the anatomy of the heart with a high degree of spatial resolution. “Bright-blood” techniques, such as cine steady-state free precession (SSFP) or gradient echo pulse sequences can delineate flow jets in valvular regurgitation. “Bright-blood” techniques are used for volumetric analysis to measure right and left ventricular volumes, ejection fractions, and myocardial mass with high efficiency [7,8].

Aim of the work:

This study targeted assessment of the role of CMR in the evaluation and grading of PR which occurs after TOF surgical repair. It also aimed to evaluate the role of CMR in the assessment of the RV dilatation and deterioration of ventricular function which are consequences of PR in comparison to 2D echocardiography.

Material and Methods

Study population:

This prospective study included 36 patients. The range of ages was from 2 years to 18 years. (Mean age \pm SD = 8.7 \pm 4.52). 19 patients (52.8%) were males, and 17 patients (47.2%) were females. It was conducted at MRI units of our radiology department over a period from March 2021 to March 2022. All patients were referred from paediatric cardiology department outpatient clinics for routine follow-up after surgical correction of TOF. This study was approved by the Institutional research board and informed consent was obtained from the guardians of all patients.

Methods:

All patients in the study were subjected to the following:

- 2D transthoracic echocardiography.
- Cardiac MRI of the heart and proximal great vessels.

Two-dimensional transthoracic echocardiography:

Echocardiography was done using standard paediatric views with colour, pulse wave, and continuous wave Doppler by phase array probe (3 MHz) on TOSHIBA Xario and GE Healthcare US unit. The following views were done:

- Sub-xiphoid (short and long-axis) views to assess the cardiac situs and both RV, LV function, IVC, atrial, and ventricular septae.
- Apical two-chamber view to assess wall motion abnormalities.
- Parasternal (short and long-axis) views to assess PR as well as RVOT size and regional wall motion.

The RV function was assessed according to tricuspid annular plane systolic excursion (TAPSE) while RV size was assessed according to dimensions in end-diastole (EDD).

Cardiac MRI of the heart and proximal great vessels:

Magnetic resonance imaging was performed within two weeks-one month from echocardiography. The examination was carried out on cardiac MRI (Ingenua 1.5T; A Philips) superconducting magnet in all cases. Infants and young children were sedated while older children who could follow instructions were not sedated. All data acquisition was retrospective ECG gated. Images were stored in digital imaging and communication in medicine (DICOM) format for processing.

The DICOM images were transmitted to the workstation (extended MR workspace 2.6.3.5, Philips medical systems Nederland B.V.) supplied by the vendor.

Image acquisition and imaging parameters:

- Localizers and interactive images through the thorax: TR (Time of repetition)=2.8, TE (Time of echo)=1.4, FOV (Field of view)=450 x 450 x 45.
- Morphologic examination with balanced SSFP according to heart rate by axial images through the thorax: TR=2.7, TE=1.36, FOV=170 x 170 x 119.
- Dynamic evaluation in 2 planes the first one determined by the axial morphologic view and the second should be perpendicular to the first to evaluate pulmonary arteries and RVOT.
- Four chamber (4-CH) SSFP cine to cover the whole heart: TR=2.3, TE=1.15, FOV=180 x 180 x 72.

- RVOT SSFP cine: TR=2.94, TE=1.47, FOV=180 x 180 x 24.
- Axial SSFP cine covering the whole heart and proximal parts of great vessels: TR=2.7, TE=1.36, FOV= 170 x 170 x 119.
- Coronal SSFP covering the whole heart and proximal great vessels: TR=2.6, TE=1.3, FOV=180 x 180 x 84.
- Short axis SSFP cine to cover the whole left ventricle: TR=2.18, TE=1.09, FOV=180 x 180 x 88.
- Phase contrast (Q-flow) for pulmonary artery and ascending aorta: TR=4.71, TE=2.98, FOV=300 x 248.
- All sequences were retrospective ECG gated.
- Each sequence scanning time was about 25-40 seconds, and the whole examination time was about 20-40 minutes for justification planimetry.

Phase-contrast cine:

Phase-contrast cine includes two types of images (Fig. 1): Magnitude and phase images, both are acquired using a bipolar gradient. In phase images, stationary tissue appears as an intermediate signal while flowing bloodstream appears as a white or black signal according to the direction of flow. The magnitude of velocity should be adjusted according to the maximum velocity. Otherwise, the phase contrast would be subjected to aliasing artifacts. The phase-contrast technique can also be applied to measure velocity in three dimensions. The magnitude images are similar to conventional white-blood gradient echo images and are used for the anatomic delineation of structures [9].

The Undesirable phase shifts generated by other factors as magnetic field in homogeneities are suppressed by the application of two velocity-encoded gradients and the subtraction of their signals [10].

Image analysis:

Cardiac magnetic resonance enabled us to evaluate the morphology of the heart and proximal great vessels through SSFP (4 chamber, axial, RVOT and SA sequences).

RV volume and function assessment was performed with multi-slice SSFP cine imaging. A parallel stack of serial images (axial) was acquired from the cardiac base to apex in the axial view images during end systole and end diastole for each slice position. End-diastolic and end-systolic volumes were calculated by summing all slices, followed by calculation of stroke volume and ejection fraction.

Flow volumes through the MPA, RPA and LPA were calculated using velocity phase maps. The region of interest (ROI) was traced around the vessel lumen (MPA, RPA and LPA) to determine the area of the vessel frame by frame. Then forward flow, regurgitant volume and fraction were calculated.

Statistical analysis:

- The description of data was done in the form of mean and standard deviation (SD). The analysis of data was done to test the statistically significant difference. The *p*-value was considered significant if $<$ or $=$ 0.05 at a confidence interval of 95%.
- Qualitative data were described using numbers and percentages. Quantitative data were described in terms of median (minimum and maximum) and mean, and standard deviation for parametric data. The significance of the obtained results was judged at the (0.05) level.
- Qualitative data: Chi-Square test for comparison of 2 or more groups.

Results

This prospective study included 36 patients. The range of ages was from 2 years to 18 years. (Mean age \pm SD=8.7 \pm 4.52). 19 patients (52.8%) were males.

Pulmonary regurge:

Regurgitant volume and fraction through the pulmonary artery were calculated for all cases via Q flow images. Pulmonary regurge was graded as mild ($<$ 20%), moderate (20-40%), and severe ($>$ 40%) [11]. Four cases (11%) had mild PR. Twelve cases (3.3%) had moderate PR. Twenty cases (55.5%) had severe PR as shown in (Table 1) and (Fig. 2).

Pulmonary regurgewas assessed for all cases with 2D echocardiography via color and wave doppler study apart from one case that could not be assessed. Comparing both modalities revealed a statistically significant difference (*p*-value=0.009) in results regarding the moderate PR group while no statistically significant difference regarding the mild (*p*-value=0.11) and severe PR group (*p*-value=0.381) as shown in (Table 1) and Fig. 3).

Right ventricular size and function:

The RV size was assessed for all cases based on the EDVI (EDV divided by the body surface area). The RV size was designated as dilated or not dilated by cardiac MRI according to the Z-score [12]. 34 cases (94%) had dilated RV while 2 cases (5.5%) had average RV size. The RV volume and function by CMR were listed in Table (2).

The results of RV size whether dilated or not were compared with 2D echocardiographic examination according to the RV Dd (Dimensions in diastole). Comparing both modalities revealed no significant difference (*p*-value=0.375) in determining whether the RV was dilated or not as shown in (Table 3).

Right ventricular function was evaluated for all cases by cardiac MRI based on the calculation of ejection fraction. The RV function was designated as impaired or preserved according to the ejection

fraction (EF) in terms of Z-score and patient's body surface area. 25 cases (69.4%) had preserved function while 11 cases (30.6%) had an impaired function as shown in (Table 3). Among those 11 cases, 8 of them had severe PR, two of them had moderate PR and only one had mild PR, suggesting strong correlation between severe PR and impaired RV function. The RV function was assessed in all cases by 2D echocardiography based on TAPSE. By echocardiography, 33 cases (92%) had preserved RV function while 3 cases (8%) had impaired RV function as shown in Table (3).

Comparing both modalities revealed statistically significant difference (p -value=0.02) in determining whether the RV function was impaired or preserved as shown in Table (3) and (Fig. 4).

Table (1): Comparison between cardiac MRI and echo regarding PR among studied cases.

PR	MRI n=36 (%)	Echo# n=35 (%)	Test of significance *Statistically significant
Mild	4 (11.1)	9 (25.7)	$p=0.11$
Moderate	12 (33.3)	3 (8.6)	$p=0.009^*$
Severe	20 (55.6)	23 (65.7)	$p=0.381$

One case Could not be assessed - Type of test used: Marginal Homogeneity Test.

Table (2): RV descriptive data of RV by CMR.

RV descriptive data n=36%		
RV EDVI:		
Mean ± SD		165±64
Median (min-max)		149.5 (79-466)
RV size:		
Normal	2	5.5
Dilated	34	95.5
RV EDV:		
Mean ± SD		171±125
Median (min-max)		142.5 (64-784)
RV ESV:		
Mean ± SD		87±100
Median (min-max)		67.8 (27-638)
RV ESVI:		
Mean ± SD		80.6±58
Median (min-max)		72 (29-379)
RV function:		
Persevered	25	69.4
Impaired	11	30.6
RV EF:		
Mean ± SD		54±8.5
Median (min-max)		54.5 (19-68)

Table (3): RV size and function by echocardiography and MRI.

	MRI n=36 (%)	ECHO** n=33 (%) 3 cases could not be assessed	Test of significance χ^2 =Chi-Square test *statistically significant
RV Size:			
Not dilated	2 (5.6)	4 (12.1)	$p=0.375$
Dilated	34 (94.4)	29 (87.9)	Test of significance
RV function:			
Preserved	25 (69.4)	33 (91.7)	$\chi^2=2.06$
Impaired	11 (30.6)	3 (8.3)	$p=0.02^*$

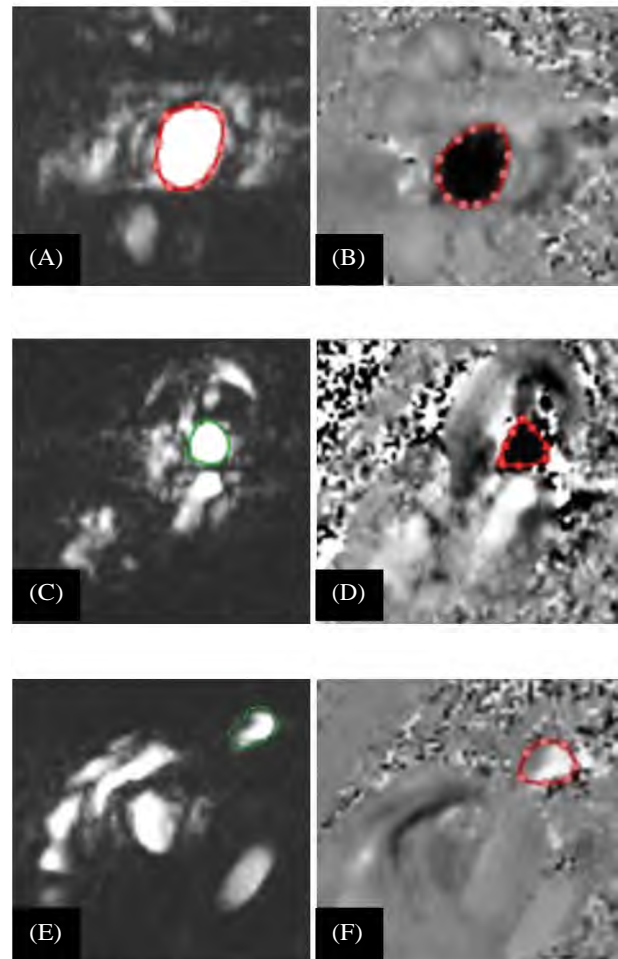


Fig. (1): Phase contrast cine: (A): Magnitude encoded image of the MPA, (b): Phase difference image of the MPA, (C): Magnitude encoded image of the RPA, (D): Phase difference image of the RPA, (E): Magnitude encoded image of the LPA, (F): Phase difference image of the LPA.

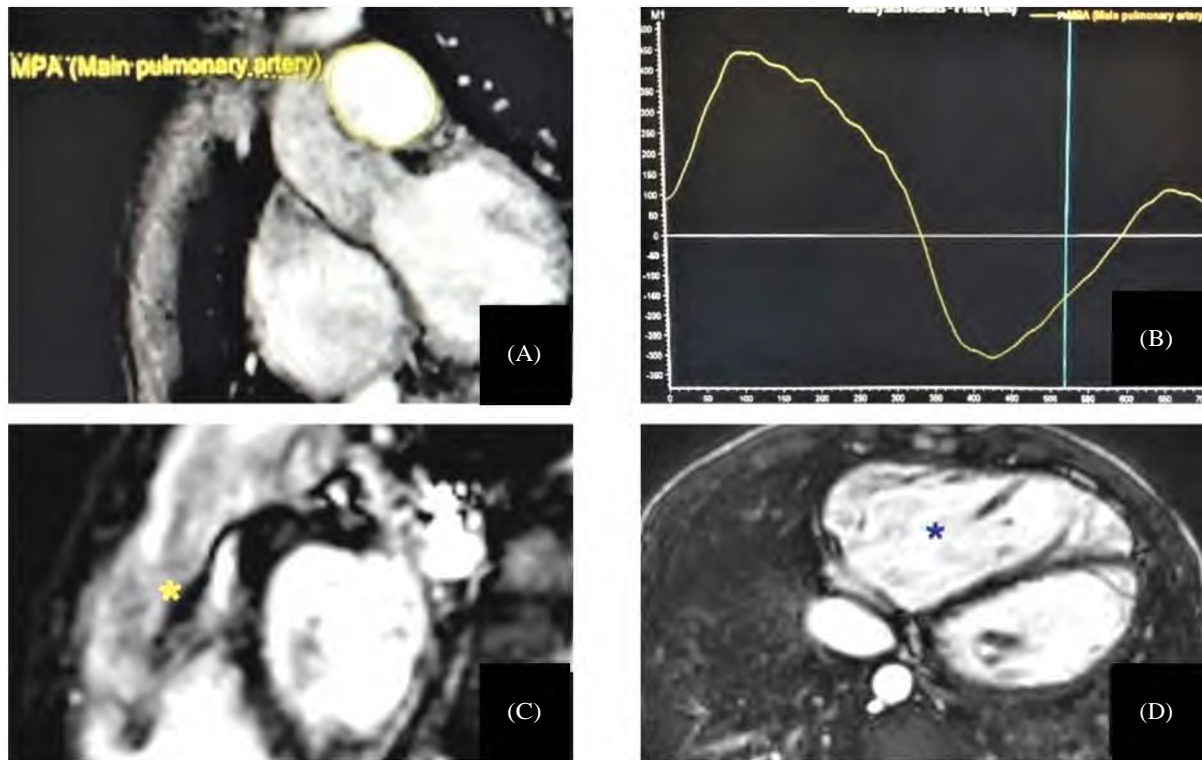


Fig. (2): Male patient aged 15 years. Height=170cm. Weight: 50 kg. (A) Phase contrast image & (B) Q-flow curve analysis showing severe PR (Regurgitant fraction=51%). (C) RVOT SSFP image: Showing regurgitant jet (yellow asterisk). (D) Axial SSFP image: Dilated hypertrophied RV (EDVI=200ml/m²) (Blue asterisk).

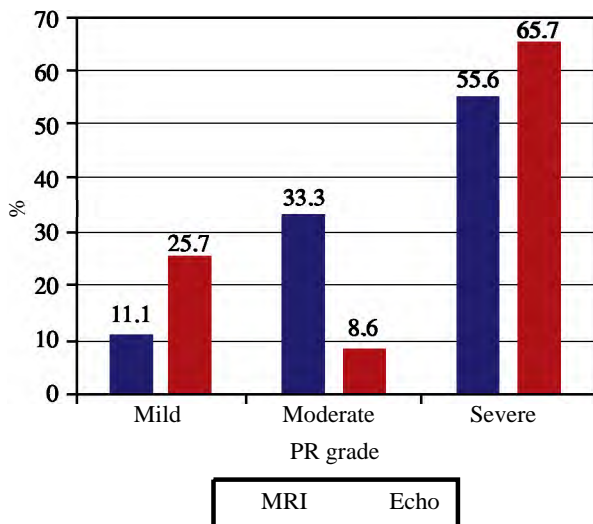


Fig. (3): Graphical representation of the comparison between cardiac MRI and echocardiography regarding PR.

Discussion

Tetralogy of Fallot is a complex congenital cardiac disease characterized by four main components: Stenosis of the RVOT, hypertrophy of the right ventricle, overriding of aorta, ventricular septal defect [1].

In this study we sought to assess the efficacy of CMR in the calculation and grading of PR following

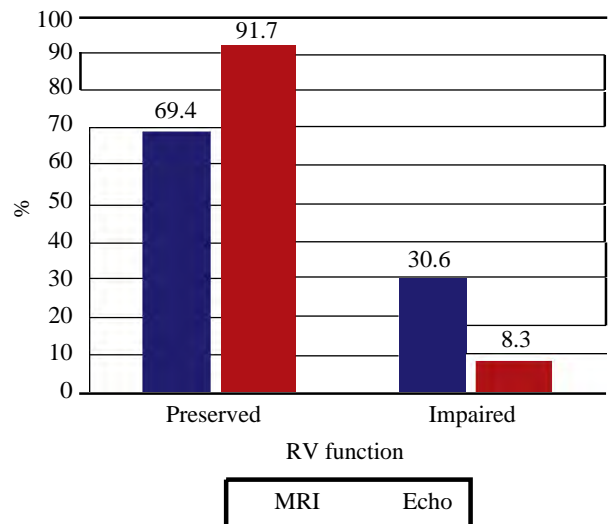


Fig. (4): Graphical representation comparing cardiac MRI and 2D echocardiography regarding RV function.

TOF surgical repair. We were also concerned with the evaluation of CMR efficacy in the assessment of RV size and function, as dilated RV and impaired RV function are consequences of PR. We also aimed to assess the relation between PR severity and RV function.

The target population of our concern was the pediatric age group. This study included 36 pa-

tients. 52.8% were males. The mean age was 8.7 ± 4.5 years. This came in agreement with Animasahun et al. [13] study in which males were affected more than females with a ratio of 1.7:1. It is worthy to mention that the later mentioned study was more concerned with statistical prevalence.

Pulmonary regurge was graded as mild (<20% RF), moderate (20-40% RF) and severe (>40% RF) according to the grading of Mercer-Rosa et al. [11]. There was good agreement between this study and both Mercer-Rosa et al. [11] and Saraya et al. [14] in the percentage of severe PR cases (55% of the cases had severe PR in our study), 40% Mercer-Rosa et al. [11] and 55% Saraya et al. [14].

As regards the grading of pulmonary regurgitation, the results of cardiac MRI were compared with 2D echocardiography. For the mild PR group, it was found that 2D echocardiography overestimated the number of PR cases (9 cases) (25.7%) compared to cardiac MRI (4 cases) (11.1%). However, this difference was not statistically significant in terms of p -value (p -value=0.11). In this research, there was a statistically significant difference between both modalities in the moderate PR group (p -value=0.009). This came in disagreement with Mercer-Rosa et al. [11] which revealed agreement between both modalities in the moderate PR group (20-40% RF). This may be explained by the difference in sample volume (moderate PR cases in our study=12) compared to (107 cases) with Mercer-Rosa et al. [11]. There was no statistically significant difference between both modalities regarding severe PR category.

In this study the RV size was assessed by cardiac MRI in comparison to 2D echocardiography. This study showed no statistically significant difference between cardiac MRI and echocardiography in determining whether the RV was dilated or not (p -value=0.375). This came in agreement with Puchalski et al. [15] which showed moderate agreement between the cardiac MRI and echocardiography (p -value=0.63) in determining the RV size. This was mostly because the comparison between MRI and echocardiography in evaluation of whether the RV is dilated or not and not evaluating the precise degree of dilatation considering the echo uses EDD while MRI uses volumetric analysis, cardiac MRI was superior in terms of quantifying the degree of dilatation by accurately calculating the EDV and EDVI.

In this study, the RV function was assessed by cardiac MRI using EF in comparison to 2D echocardiography using TAPSE. There was statistically significant difference between both modalities (p -value=0.02). This came in a good agreement with Puchalski et al. [15]. The later study showed poor agreement between the two modalities in 2 categories (13 cases). However, in the remaining categories there was a relative agreement between the two modalities. This may be explained by the differ-

ence in the method of comparison. As in our study, the study population was not categorized in terms of RV function impairment, while in Puchalski et al. [15], patients were categorized in terms of RV function into normal, mild, moderate and severely diminished.

In this study, 11 out of 36 cases had impaired RV function. Among those 11 cases, eight of the cases (73%) had severe PR, two had moderate PR and only one had mild PR. This comes in excellent agreement with (Eyskens B et al.) which stated that the RV function indices in patients with severe PR were significantly lower than patients who had mild or moderate PR [16].

Limitations: This study had variable limitations, for example, limited number of cases, comparison was made between CMR and 2D echocardiography not 3D. Future multicenter studies with larger sample volume are highly recommended.

Conclusions:

Cardiac magnetic resonance is an important tool in evaluating and grading the degree of PR. There was a statistically significant difference between cardiac magnetic resonance and echocardiography in the quantification of PR following surgical repair of TOF regarding moderate category of regurgitation while no statistically significant difference could be detected between both modalities regarding mild and severe categories. CMR was more accurate than echocardiography in the assessment and quantification of RV function. There was a positive correlation between the severity of PR and impairment of RV function.

References

- 1- WILSON R., ROSS O. and GRIKSAITIS MJBe: Tetralogy of fallot. BJA education, 19 (11): 362, 2019.
- 2- SENTHILNATHAN S., DRAGULESCU A. & MERTENS LJJoCE: Pulmonary regurgitation after tetralogy of fallot repair: A diagnostic and therapeutic challenge. Journal of Cardiovascular Echography, 23 (1): 1, 2013.
- 3- AMMASH N.M., DEARANI J.A., BURKHART H.M. and CONNOLLY HMJChd. Pulmonary regurgitation after tetralogy of Fallot repair: clinical features, sequelae, and timing of pulmonary valve replacement. Congenital heart disease, 2 (6): 386-403, 2007.
- 4- OOSTERHOF T., VAN STRATEN A., VLIEGEN H.W., MEIJBOOM F.J., VAN DIJK A.P., et al.: Preoperative thresholds for pulmonary valve replacement in patients with corrected tetralogy of Fallot using cardiovascular magnetic resonance. Circulation, 116 (5): 545-51, 2007.
- 5- WALD R.M., VALENTE A.M., GAUVREAU K., BABU-NARAYAN S.V., ASSENZA G.E., et al.: Cardiac magnetic resonance markers of progressive RV dilation and dysfunction after tetralogy of Fallot repair. Heart, 101 (21): 1724-30, 2015.

- 6- KILNER P.J., GEVA T., KAEMMERER H., TRINDADE P.T., SCHWITTER J., et al.: Recommendations for cardiovascular magnetic resonance in adults with congenital heart disease from the respective working groups of the European Society of Cardiology. *European Heart Journal*, 31 (7): 794-805, 2010.
- 7- ORDOVAS K.G., MUZZARELLI S., HOPE M.D., NAEGER D.M., KARL T., et al.: Cardiovascular MR imaging after surgical correction of tetralogy of Fallot: Approach based on understanding of surgical procedures. *Radiographics*, 33 (4): 1037-52, 2013.
- 8- HAGGERTY C.M., SUEVER J.D., PULENTHIRAN A., MEJIA-SPIEGELER A., WEHNER G.J., et al.: Association between left ventricular mechanics and diffuse myocardial fibrosis in patients with repaired Tetralogy of Fallot: a cross-sectional study. *Journal of Cardiovascular Magnetic Resonance*, 19 (1): 1-10, 2017.
- 9- CHAI P. and MOHIADDIN RJJ: How we perform cardiovascular magnetic resonance flow assessment using phase-contrast velocity mapping. *Journal of Cardiovascular Magnetic Resonance*, 7 (4): 705-16, 2005.
- 10- SRICHAJ M.B., LIM R.P., WONG S. and LEE VSJ: Cardiovascular applications of phase-contrast MRI. *Journal of Cardiovascular Magnetic Resonance*, 192 (3): 662-75, 2009.
- 11- MERCER-ROSA L., YANG W., KUTTY S., RYCHIK J., FOGEL M., et al.: Quantifying pulmonary regurgitation and right ventricular function in surgically repaired tetralogy of Fallot: A comparative analysis of echocardiography and magnetic resonance imaging. *Circulation: Cardiovascular Imaging*, 5 (5): 637-43, 2012.
- 12- OLIVIERI L.J., JIANG J., HAMANN K., LOKE Y-H., CAMPBELL-WASHBURN A., et al.: Normal right and left ventricular volumes prospectively obtained from cardiovascular magnetic resonance in awake, healthy, 0-12 year old children. *Journal of Cardiovascular Magnetic Resonance*. *Journal of Cardiovascular Magnetic Resonance*, 22 (1): 11, 2020.
- 13- ANIMASAHUN B.A., MADISE-WOBO A.D., OMOKHODION S.I., NJOKANMA OFJJoC and RESEARCH T.: Children with tetralogy of Fallot in an urban centre in Africa. *Journal of Cardiovascular and Thoracic Research*, 7 (4): 168, 2015.
- 14- SARAYA S., WOODARD P., BHALLA S., GUTIERREZ F., SARAYA M., et al.: Cardiac MRI in evaluation of post-operative congenital heart disease and complications. *Egyptian Journal of Radiology and Nuclear Medicine*, 51: 1-12, 2020.
- 15- PUCHALSKI M.D., WILLIAMS R.V., ASKOVICH B., MINICH L.L., MART C., et al.: Assessment of right ventricular size and function: Echo versus magnetic resonance imaging. *Congenital heart disease*, 2 (1): 27-31, 2007.
- 16- EYSKENS B., BROWN S.C., CLAUS P., DYMARKOWSKI S., GEWILLIG M., et al.: The influence of pulmonary regurgitation on regional right ventricular function in children after surgical repair of tetralogy of Fallot. *European Journal of Echocardiography*, 11 (4): 341-5, 2010.

تقييم وتصنيف الإرتجاع (القلس) الرئوى بعد الإصلاح الجراحى لرباعية فالو بإستخدام التصوير بالرنين المغناطيسى للقلب

يعد الرنين المغناطيسى للقلب وسيلة هامة لتقييم وتصنيف الإرتجاع الرئوى فى حالات ما بعد الإصلاح الجراحى لرباعية فالو.

لقد كان هناك إختلاف إحصائى هام يعدد به بين الموجات الفوق صوتية على القلب والرنين المغناطيسى للقلب بخصوص تقييم الإرتجاع الرئوى فى حالات ما بعد الإصلاح الجراحى لرباعية فالو وتحديد كميته فيما يخص الدرجة المتوسطة من الإرتجاع الرئوى من خلال هذه الدراسة. ولكن لم يكن هناك إختلاف إحصائى بين الوسيلتين فيما يخص الفئتين البسيطة والشديدة من الإرتجاع الرئوى.

يعد الرنين المغناطيسى للقلب أكثر دقة من الموجات الفوق صوتية على القلب فيما يخص تقييم وتحديد وظيفة البطين الأيمن لقد كان هناك علاقة إيجابية بين شدة الإرتجاع الرئوى ومدى قصور وظيفة البطين الأيمن.