

## Endoscopic Removal of Third Ventricular Colloid Cyst, A Single Institution, 6-Year Experience

HESHAM A. ELSHITANY, M.D.; EHAB A. ELREFAIE, M.D. and AHMED A. ABDALLAH, M.D.

*The Department of Neurosurgery, Faculty of Medicine, Cairo University*

### Abstract

**Background:** Third ventricular colloid cysts are rare benign lesion that can usually cause obstructive hydrocephalus, increased intracranial pressure and sometimes death. Surgery for these lesions was usually performed through a craniotomy using the surgical microscope. With the introduction of the neuroendoscopy, surgical resection has been shifting to the use of the endoscope.

**Aim of Study:** This study aimed at studying the feasibility and complications of endoscopic resection of third ventricular colloid cysts.

**Patients and Methods:** Between 2013 and 2019, all patients (13) who received surgical endoscopic removal of colloid cysts of the third ventricle at Cairo University Hospital in Cairo, Egypt, were included in the study. Patient charts were assessed for information on pre-and postoperative symptoms, as well as complications. MRI or CT scans were used to measure the maximum cyst diameter and Evans' index. The average period of follow-up was 34 months. Three patients were lost to follow-up.

**Results:** The average patient age was 34 years old ( $\pm 8.5$ ) at time of surgery. We have got 5 females and 8 males. Mean postoperative hospital stay was 13.5 days ( $\pm$ SD 11.3). Table (1) depicts the present symptoms, surgical improvement, and complications. Six patients (46%) presented with hydrocephalus symptoms. When the colloid cyst was removed, an EVD was implanted to monitor intracranial pressure for a maximum of two days after surgery. Postoperative complications happened in 3 cases (23%) of the cases.

**Conclusion:** This surgical method employs burr holes rather than craniotomies, with no retraction of the brain, needs a shorter operational time, a shorter hospital stays, and results in greater of satisfaction levels for the patient. Furthermore, the endoscopic technique is safer and more effective, with reduced rates of recurrence and complications.

**Key Words:** *Colloid cyst – Endoscopic surgery – Open microsurgery – Hydrocephalus.*

### Introduction

**THIRD** ventricular colloid cysts are rare benign tumors that afflict around 1 in every 8500 persons [1]. By obstructing the foramina of Monroe, they can cause acute obstructive hydrocephalus leading to sudden death [2]. The fatality rate of cerebral herniation secondary to ventricular obstruction is estimated to be 5% [1]. Open microsurgery has typically been used to treat colloid cysts. However, developments in endoscopic technology and the introduction of technological subtleties to the endoscopic technique have made it the preferred method in numerous neurosurgery institutes [3]. The mortality rate from cerebral herniation induced by ventricular obstruction is estimated to be 5%.

Endoscopic surgery (ES), has been shown to have much less complications, a reduced operational period, and a shorter hospitalization time [4].

Furthermore, ES has progressed in recent decades, with a nearly equivalent rate of entire resection compared to microsurgical procedures [5].

The purpose of our study is to examine the postoperative prognosis and complications in patients who had endoscopic removal of third ventricle colloid cysts at our institution.

### Patients and Methods

Between 2013 and 2019, all patients (13) who received surgical endoscopic removal of colloid cysts of the third ventricle at Cairo University Hospital in Cairo, Egypt, were included in the study. The medical records of all patients who underwent surgery were revised. Patient charts were assessed for information on pre-and postoperative symptoms, as well as complications. Pathology confirmed the diagnosis of a colloid cyst. The diagnosis was based on a combination of radiographic and intraoperative evidence in situations where the histopathological report was unavailable. MRI or CT scans were used to measure the maximum cyst diameter. (Figs. 1,2)

Correspondence to: Dr. Hesham A. Elshitany,  
E-Mail: [Hisham.elshitany@kasralainy.edu.eg](mailto:Hisham.elshitany@kasralainy.edu.eg)

The average period of follow-up was 96 months. Three patients were lost to follow-up. Table (1) lists the characteristics of the patient cohort.

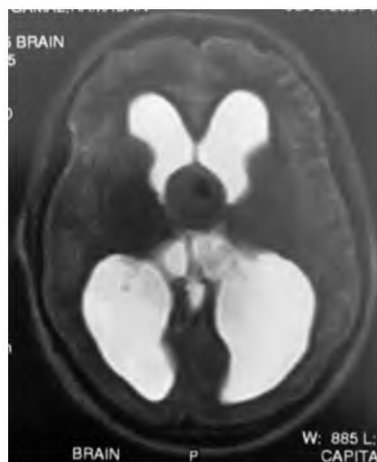


Fig. (1): MRI brain of a 33 year old male patient with headache, vomiting and blurring of vision for 2 months, the T2 sequence showed a well circumscribed third ventricular lesion.

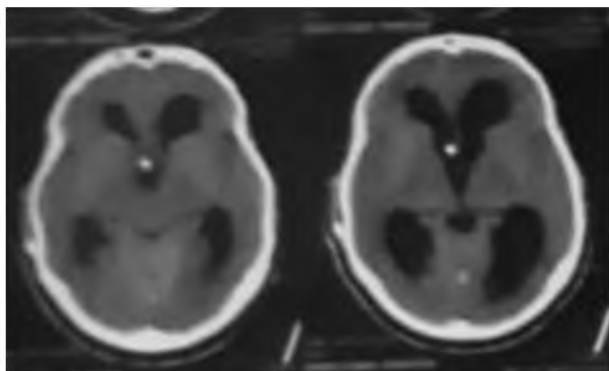


Fig. (2): The post-operative CT of the same patient showing the removal of the lesion and placement of shunt.

Table (1): Characteristics of the patients cohort, and surgical results.

	Number
<b>Sex:</b>	
Males	8
Females	5
<b>Age</b>	34±8.54 years
<b>Hospital stay</b>	13.5±11.7 days
<b>Symptoms:</b>	
Headache, Visual affection, Vomiting	11
Memory	1
Visual affection alone	1
<b>Cyst size</b>	174.5±60 mm <sup>3</sup>
<b>Follow-up</b>	34±23 months
<b>Complications:</b>	
Weakness	1
Infection	1
Bleeding	2

#### Surgical procedure:

After the meninges were opened, a rigid endoscope was inserted. On the right side, a burr hole was drilled roughly 3cm lateral to Kocher's site for endoscopic resection. A line drawn from the cyst center to foramen of Monroe and projecting to the surface of the skull determines the trajectory line for surgery and the site of the burr hole. Endoscopes used were rigid 0-degree endoscopes (Gaab system, 6.5mm outer diameter, LOTTA system, 6.8mm outer diameter, [Karl Storz, Tuttlingen, Germany]).

The frontal horn of the right ventricle, which contained the colloid cyst was incised. Bipolar forceps were used to coagulate the cyst wall and pierce it. A Fogarty balloon introduced through the cyst wall was inflated to widen the aperture. Grasping forceps can also be used to enlarge the hole in the cyst wall.

The contents of the cyst were aspirated using a small catheter put via the shaft of the endoscope. The capsule was then detached from the roof of the third ventricle and grasped using endoscopic forceps. The cyst was then removed through the burr hole with the endoscope. Finally, a 30-degree lens was used to evaluate the third ventricular roof for any residual of the cyst wall. When a little bleed ensued, an external ventricular drain was implanted.

#### Statistical analysis:

IBM® SPSS® Statistics, version 24.0, was used for all analyses (Chicago, IL, USA). Symptoms and complications were recorded as dichotomous variables, which were then evaluated using Fisher's exact test. The operating time and hospital stay were shown as means ± SD. The Mann-Whitney U-test was used to evaluate non-normally distributed data that were presented as medians and quartiles. All the tests were set to be two-tailed, with an alpha of 0.05.

## Results

Fifty-six individuals were operated on for colloid cysts of the third ventricle, with 13 being done endoscopically. The average patient age was 34 years old (±8.5) at time of surgery. We have got 5 females and 8 males.

Mean postoperative hospital stay was 13.5 days (±11.3). Table (1) depicts the present symptoms, surgical improvement, and complications. Six patients (46%) presented with hydrocephalus symptoms. When the colloid cyst was removed, an EVD was implanted to monitor intracranial pressure for a maximum of two days after surgery.

Postoperative complications happened in 3 cases (23%) of the cases, one of them had memory deficit that improved 6 months later, one had intraoperative injury of the lateral wall of the lateral ventricle resulting in permanent motor deficit, and one had

postoperative infection resulting in death after 35 days of hospital stay. The cysts were situated in the anterior third ventricle, resulting in partial closure of the Monroe foramina and subsequent obstructive hydrocephalus in all individuals except one.

Presenting symptoms included headache in 10 patients with (76%); vomiting in 3 of them visual affection in 3 of them (23%), memory and concentration affection in 2 patients (15%).

Thirteen individuals had endoscopic colloid cyst excision. The cysts were completely emptied in all cases. In nine cases, total cyst excision was accomplished (69%). Because of strong adherence to the telachoroidea at the roof of the third ventricle, small remnants of cyst capsule had to be left behind in two patients, while intraoperative complications allowed only partial resection of the cyst in two cases with immediate intraoperative placement of EVD, which was later converted to septostomy and shunt insertion.

Except for one case, histological examination was undertaken, and a colloid cyst was verified.

#### Discussion

Endoscopic colloid cyst removal has become a feasible alternative to microsurgical procedures due to ongoing innovations in endoscopic techniques and tools, as well as favorable long-term outcomes in endoscopically treated patients [6].

Even though the endoscopic removal of colloid cysts has become more common in the last twenty years, we still have controversy regarding the best way to treat colloid cysts. Although endoscopic cyst excision has a low complication rate and a favorable short-term prognosis, it is typically not drastic [7-9].

Although early microsurgical studies had a greater complication rate, current series have demonstrated outstanding outcomes with a high overall resection rate and low problems.

Despite having little research published about the endoscopic therapy of third ventricular colloid cysts, our findings that endoscopic surgery had a shorter mean operational time and a shorter mean hospital stay than open surgery are consistent with earlier research [10-12]. In the endoscopic procedures, a shorter operating time is related to smaller incisions and a more advantageous approach angle to the colloid cyst point of attachment in the roof of the third ventricle.

When removing a colloid cyst, one should position the burr hole more anteriorly than when performing an endoscopic third ventriculostomy.

Prior to surgery, the cyst's position in relation to the foramen of Monroe and the roof of the third ventricle must be identified. A transforaminal technique

can be used to reach most lesions. A transeptal-interforaminal technique could be used to approach a retroforaminal cyst of the third ventricle that is situated in while projecting in the floor of the lateral ventricles [13].

Patients with colloid cysts are more prone to cognitive impairments, owing to the cysts near proximity to the fornices that constitute the Papez circuit [14,15].

Memory problems have been linked to disruptions in the fornical circuit rather than ventricular hypertrophy alone [16].

We have encountered only one case of memory affection that lasted for 6 months, then spontaneously improved.

Over an average follow-up period of 96 months, we found single port endoscopy secure and successful, achieving gross total resection (GTR) in 69 % of cases with no recurrence or hydrocephalus. Despite the fact that the range of GTR has greatly improved in endoscopic series, several metanalysis documented an overall GTR of 58% to 78.5% in endoscopy [17,18].

Many studies either had short follow-up or found up to 7.5 % recurrence following endoscopy [19]. In 78% of patients, our aggressive therapy resulted in long-term remission, with shunt reliance in 15.3 %, whereas other authors reported shunt dependency ranging from 4% to 9% [20].

Although the majority of research encourage the endoscopic resection of colloid cysts as a safe and successful method, other series claimed that in some circumstances, conversion to an open procedure may be necessary for full resection [21]. In our series, we did not need to transition to an open resection.

After endoscopic removal of colloid cysts, there have been instances of seizures, reduced memory, hemiparesis, and cerebellar bleeding [20]. We also observed one case of septic ventriculitis, one patient with prolonged weakness, and two patients who ultimately required a ventriculoperitoneal shunt. Previously, authors found a considerably decreased complications rate in endoscopic resection compared to microsurgical resection of colloid cysts, with a comparable removal rate [19].

We reported a recurrence in three patients (23%) which is associated with partial or incomplete removal of cyst wall, this could be compared to the recurrence rate in Vorbau et al series who reported 10% recurrence rate after endoscopic removal of colloid cysts [22], and Zohdi et al., who reported no recurrence rate in a mean follow-up period of 4 years [23], we contributed this to the very thick consistency of the cyst content in one case, the posterior

location of the cyst in another one, and to the occurrence of intraoperative bleeding in the last case of them.

Endoscopic resections of colloid cysts might be complicated due to their posterior position. The surgeon's ability to execute a thorough resection is limited by his inability to do 2-handed microdissection with the endoscope, notably regarding the attachment of the colloid cyst to the roof of the third ventricle.

In their retrospective report of 243 cases of endoscopic colloid cyst surgery, Connolly et al., found a mean hospital stay of 5.7 days [24], we have reported a mean stay of 13.5 days, this difference arises from the presence of an outstanding case of CSF infection who stayed for 35 days in hospital.

#### Conclusion:

The ideal surgical approach for removal of colloid cysts either using endoscopy or microsurgery is still being debated in the literature. This arises mainly from the anatomical location of the cyst hanging from the roof of the third ventricle.

Several advantages of using an endoscopic technique to treat colloid cysts have been described. This surgical method employing burr holes rather than craniotomies, with no retraction of the brain, needs a shorter operational time, a shorter hospital stay, and results in greater of satisfaction levels for the patient. Furthermore, the endoscopic technique is safer and more effective, with reduced rates of recurrence and complications.

#### References

- HAMER PC DE W., VERSTEGEN M.J.T., HAAN R.J. DE, VANDERTOP W.P., THOMEER R.T.W.M., MOOIJ J.J.A., et al.: High risk of acute deterioration in patients harboring symptomatic colloid cysts of the third ventricle. *Journal of Neurosurgery* [Internet]. Jun 1 [cited 2021 Oct 30]; 96 (6): 1041-5. Available from: <https://thejns.org/view/journals/j-neurosurg/96/6/article-p1041.xml>, 2002.
- BEAUMONT T.L., LIMBRICK D.D., RICH K.M., WIPOLD F.J. and DACEY R.G.: Natural history of colloid cysts of the third ventricle. *Journal of Neurosurgery* [Internet]. Dec 1 [cited 2021 Oct 30]; 125 (6): 1420-30. Available from: <https://thejns.org/view/journals/j-neurosurg/125/6/article-p1420.xml>, 2016.
- FARAHMAND D., STRIDH J., ZIEGELITZ D. and TISELL M.: Endoscopic versus open microsurgery for colloid cysts of the third ventricle. <https://doi.org/10.1080/0268869720211925872> [Internet]. [cited 2021 Oct 30]; Available from: <https://www.tandfonline.com/doi/abs/10.1080/02688697.2021.1925872>, 2021.
- O'NEILL A.H., GRAGNANIELLO C. and LAI L.T.: Natural history of incidental colloid cysts of the third ventricle: A systematic review. *Journal of Clinical Neuroscience*, Jul. 1; 53: 122-6, 2018.
- WILSON D., FUSCO D. and WAIT S.: Neurosurgery PN-W, 2013 undefined. Endoscopic resection of colloid cysts: Use of a dual-instrument technique and an anterolateral approach. Elsevier [Internet]. [cited 2021 Oct 30]; Available from: <https://www.sciencedirect.com/science/article/pii/S1878875012007929>,
- HELLWIG D., BAUER B.L., SCHULTE M., GATSCHER S., RIEGEL T. and BERTALANFFY H.: Neuroendoscopic Treatment for Colloid Cysts of the Third Ventricle: The Experience of a Decade. *Neurosurgery* [Internet]. Mar. 1 [cited 2021 Nov 3]; 52 (3): 525-33. Available from: <https://academic.oup.com/neurosurgery/article/52/3/525/2732343>, 2003.
- LEWIS A.I., CRONE K.R., TAHA J., VAN LOVEREN H.R., YEH H.S. and TEW J.M.: Surgical resection of third ventricle colloid cysts: Preliminary results comparing transcallosal microsurgery with endoscopy. *Journal of Neurosurgery* [Internet], Aug. 1 [cited 2021 Dec 28]; 81 (2): 174-8. Available from: <https://thejns.org/view/journals/j-neurosurg/81/2/article-p174.xml>, 1994.
- TIRAKOTAI W., SCHULTE D.M., BAUER B.L., BERTALANFFY H. and HELWIG D.: Neuroendoscopic surgery of intracranial cysts in adults. *Child's Nervous System*, Nov. 20 (11-12): 842-51, 2004.
- SAMADIAN M., EBRAHIMZADEH K., MALOUMEH E.N., JAFARI A., SHARIFI G., SHIRAVAND S., et al.: Colloid Cyst of the Third Ventricle: Long-Term Results of Endoscopic Management in a Series of 112 Cases. *World Neurosurgery*, Mar. 1; 111: e440-8, 2018.
- HD B., P D., JA G., C L.G., R N., B J., et al.: Long-term results of the neuroendoscopic management of colloid cysts of the third ventricle: A series of 90 cases. *Neurosurgery* [Internet], Jan [cited 2021 Oct. 31]; 68 (1): 179-87. Available from: <https://pubmed.ncbi.nlm.nih.gov/21150763/>, 2011.
- AB S., ZS M. and JK L.: Endoscopic versus microsurgical resection of colloid cysts: a systematic review and meta-analysis of 1,278 patients. *World neurosurgery* [Internet], Dec. 1 [cited 2021 Oct. 31]; 82 (6): 1187-97. Available from: <https://pubmed.ncbi.nlm.nih.gov/24952223/>, 2014.
- GRONDIN R.T., HADER W., MACRAE M.E. and HAMILTON M.G.: Endoscopic versus microsurgical resection of third ventricle colloid cysts. *Canadian Journal of Neurological Sciences*, 34 (2): 197-207, 2007.
- VIALOGO J.G.G.: Acesso endoscópico transepto-interforniceal para cistoscolóides: Relato de caso. *Arquivos de Neuro-Psiquiatria* [Internet], [cited 2021 Nov. 3]; 58 (3 B): 939-46. Available from: <http://www.scielo.br/j/anp/a/HmBLYdySwZZf7Q68HjB3Gqg/?lang=pt>, 2000.
- HARRIS RUSSO R. and KINDT G.W.: A neuroanatomical basis for the bobble head doll syndrome. *Journal of Neurosurgery*, 41 (6): 720-3, 1974.
- SRIDHAR S., PURKAYASTHA M., DUTTA P., DHAN-DAPANI S.S. and MUKHERJEE K.K.: Third ventricular cyst presenting with bobble head doll movements and tactile hallucinations. *Neurology India*, Jan. 61 (1): 87-8, 2013.

- 16- LAWRENCE J.E., NADARAJAH R., TREGGER T.D. and AGIUS M.: Neuropsychiatric Manifestations of Colloid Cysts: A review of the literature. *Psychiatria Danubina*, Sep. 1; 27: S315-20, 2015.
- 17- SHEIKH A.B., MENDELSON Z.S. and LIU J.K.: Endoscopic Versus Microsurgical Resection of Colloid Cysts: A Systematic Review and Meta-Analysis of 1278 Patients. *World Neurosurgery*, Dec. 1; 82 (6): 1187-97, 2014.
- 18- SETHI A., CAVALCANTE D. and ORMOND D.R.: Endoscopic Versus Microscopic Transcallosal Excision of Colloid Cysts: A Systematic Review in the Era of Complete Endoscopic Excision. *World Neurosurgery*, Dec. 1; 132: e53-8, 2019.
- 19- CONNOLLY I.D., JOHNSON E., LAMSAM L., VEERAVAGU A., RATLIFF J. and LI G.: Microsurgical vs. Endoscopic excision of colloid cysts: An analysis of complications and costs using a longitudinal administrative database. *Frontiers in Neurology*, Jun. 9; 8 (JUN), 2017.
- 20- SABANCI P.A., ARAS Y., ALI A., UNAL T.C., DOLEN D., SENCER S., et al.: Transcortical removal of third ventricular colloid Cysts: Comparison of conventional, guided microsurgical and endoscopic approaches and review of the literature. *Turkish Neurosurgery*, 27 (4): 546-57, 2017.
- 21- HELLER R.S. and HEILMAN C.B.: Colloid Cysts: Evolution of Surgical Approach Preference and Management of Recurrent Cysts. *Operative Neurosurgery* [Internet], Jan 1 [cited 2021 Dec 31]; 18 (1): 19-25. Available from: <https://academic.oup.com/ons/article/18/1/19/5440570>, 2020.
- 22- VORBAU C., BALDAUF J., OERTEL J., GAAB M.R. and SCHROEDER H.W.S.: Long-Term Results After Endoscopic Resection of Colloid Cysts. *World Neurosurgery*, Feb. 1; 122: e176-85, 2019.
- 23- ZOHDY A. and ELKHESHIN S.: Endoscopic approach to colloid cysts. *Minimally invasive neurosurgery : MIN* [Internet], Oct [cited 2022 Jan 2]; 49 (5): 263-8. Available from: <https://pubmed.ncbi.nlm.nih.gov/17163338/>, 2006.
- 24- CONNOLLY I.D., JOHNSON E., LAMSAM L., VEERAVAGU A., RATLIFF J. and LI G.: Microsurgical vs. Endoscopic Excision of Colloid Cysts: An Analysis of Complications and Costs Using a Longitudinal Administrative Database [Internet]. Vol. 8, *Frontiers in Neurology*, p. 259. Available from: <https://www.frontiersin.org/article/10.3389/fneur.2017.00259>, 2017.

## دراسة استخدام المنظار المخي لاستئصال امراض التكييس الغرواني للبطين الثالث المخي

الخلفية: تعد التكييسات الغروانية بالبطين الثالث المخي احدى الأورام المخية الحميدة قليلة الشيوع والتي تحمل تحديات جراحية كثيرة تتعلق بمكان تواجدها وخطورة تضرر الانسجة المحيطة بها ووجود استسقاء دماغى ناتج عنها من عدمه مما يستلزم الاختيار الأمثل والأكثر امانا للمريض سواء.

الطريقة: وقد أجريت هذه الدراسة لتحليل وبيان نتائج حالات التكييس الغروانى التى تم استئصالها باستخدام المنظار المخي فى قسم جراحة المخ والأعصاب بكلية الطب جامعة القاهرة فى الفترة من ٢٠١٣-٢٠١٩.

النتائج: وقد أظهرت الدراسة مدى كفاءة الاستئصال باستخدام المنظار المخي الجراحى وتفضيله عن الجراحة الميكروسكوبية فيما يتعلق من عدم الاحتياج لرفع عظام القحف و استبدال ذلك بمجرد ثقب الجمجمة وسهولة ووضوح التعامل مع الانسجة المحيطة والوصول للتكييس دون الحاجة لإزاحة المخ وتقليل مدة الاجراء الجراحى وفترة الإقامة بالمستشفى ما بعد الجراحة وما ترتب على ذلك من زيادة معدلات الأمان الجراحية وتقليل المضاعفات اثناء وبعد الجراحة.