

## Comparative Study between Medial Rectus Muscle Resection versus Plication When Coupled with Lateral Rectus Muscle Recession in Treatment of Exotropia

AHMED A. ELBARAWY, M.D.; ABDALLA EL AMIN, M.D.; AMR M. MOHAMED, M.Sc. and AHMED F. GABR, M.D.

The Department of Ophthalmology, Faculty of Medicine, Aswan University

### Abstract

**Background:** There are many reasons to perform a strabismus surgery, either to provide binocular single vision, improve cosmesis, restore normal eye contact and/or enhance the quality of life.

**Aim of Study:** The purpose of this study is to compare between medial rectus muscle plication versus resection when coupled with lateral rectus recession as regard efficacy and possible complications in treatment of exotropia.

**Patients and Methods:** This study was carried out in Ophthalmology Department at Aswan University Hospital between 2019 and 2020 on 40 patients with exotropia. The first 20 patients were operated by the plication procedure, while, the other 20 patients were operated by the resection procedure. This study was a randomized controlled study.

**Results:** Plication technique was comparable to resection technique as there were no significant differences as regard post-operative results, but plication technique could be safer in prevention of lost muscle and anterior segment ischemia. Also, plication technique was of shorter operation time.

**Conclusion:** MR muscle plication is an alternative easier, safer and faster technique to resection when coupled with lateral rectus recession in treatment of exotropia.

**Key Words:** Strabismus – Plication – Resection – Recession.

### Introduction

**STRABISMUS** surgery usually serves to align the visual axes to provide binocular single vision, improve cosmesis, restore normal eye contact and/or enhance the quality of life [1]. It usually involves slackening an overacting Extraocular Muscle (EOM) most often by recession, tightening an underacting muscle (by resection, tuck or plication) or altering the pull of the vector forces by changing the insertion site of a muscle, that is transposition.

**Correspondence to:** Dr. Amr M. Mohamed,  
**E-Mail:** [amr.moussa.mhmd@gmail.com](mailto:amr.moussa.mhmd@gmail.com)

Tightening of the EOM commonly involves resection, where a planned length of EOM-tendon complex is excised. An alternative of tightening is plication, where a planned length of EOM-tendon complex is folded upon its self and reattached to the muscle insertion. Chaudhuri and Demer, [2] reported that rectus muscle plication is a useful strabismus surgical procedure and called it a modified rectus tuck. The modification involved suturing the muscle to sclera, in contrast to a tuck that sutures the muscle to its self.

Plication is less invasive, more easily reversible, may impinge less on anterior segment circulation and does not require muscle disinsertion. Also, thus minimizing the risk of lost muscle.

### Patients and Methods

Patients who were eligible to the study were recruited from the outpatient clinic of Ophthalmology Department at Aswan University Hospital along the period of the study, patients were randomized as, the first 20 patients were operated by the plication procedure, while, the other 20 patients were operated by the resection procedure. This study was a randomized controlled study.

#### *Inclusion criteria:*

a- Primary and sensory exotropia in the age above 4 years old.

#### *Exclusion criteria:*

- a- Previous squint surgery.
- b- Restrictive strabismus.
- c- Duane syndrome.

*Pre-operative evaluation:*

All cases were subjected to full ophthalmological evaluation including; full cycloplegic refraction, fundus examination, best corrected visual acuity when possible and ocular motility. Measuring the angle of deviation was done by prism and cover test. Systemic work-up for general anesthesia for the age was done.

All the eligible patients from the outpatient clinic along the period of the study were prospectively randomized into 2 groups, each group include 20 patients:

Group (A) were operated by lateral rectus muscle recession with medial rectus muscle plication (R & P). Group (B) were operated by lateral rectus muscle recession with medial rectus muscle resection (R & R).

*Surgical steps:**Rectus muscle plication:*

General anesthesia was used in all cases. The patient's eyes were sterilized using betadine solution and draped and a lid speculum was applied. A limbal conjunctival incision was done in all cases to expose the extraocular muscle. An inferior radial incision was performed, then a second incision through the tenon's capsule. Westcott scissors were used to undermine the anterior Tenon's capsule and conjunctiva. A limbal periotomy was performed, and then a second radial incision was

performed superiorly. The muscle was hooked, was freed from the check ligaments and the intermuscular septae by using blunt and sharp dissection.

This was done further beyond the designated resection distance to help easy plication of the muscle. The amount of plication was measured by a caliper. The muscle was secured with a 5/0 Ethibond double armed suture with spatulated needle placed at the position indicated by the caliper. The needles were passed through half thickness muscle, starting in the center of the muscle, aiming perpendicular to the muscle fibers, towards the edge of the muscle. A 2mm locking bite was then placed at the edge of the muscle. This was repeated in the other side of the muscle. The anterior ciliary arteries were avoided as they lie superficial to the muscle and the sutures were placed somehow deeper. The needles were then passed through the tendon at the insertion. The muscle was advanced by pulling on the double armed suture. This could be facilitated by applying counter traction on the muscle by pulling the globe in the direction of action of the muscle. A double throw overhand knot was secured and the needle holder or non-toothed forceps pinched the knot so it did not loosen then a second throw was placed. The conjunctiva was closed using interrupted inverted 8/0 vicryl sutures. An ointment of 0.3% of tobramycin and 0.1% of dexamethasone is applied within palpebral fissure. Then, the eye was patched.

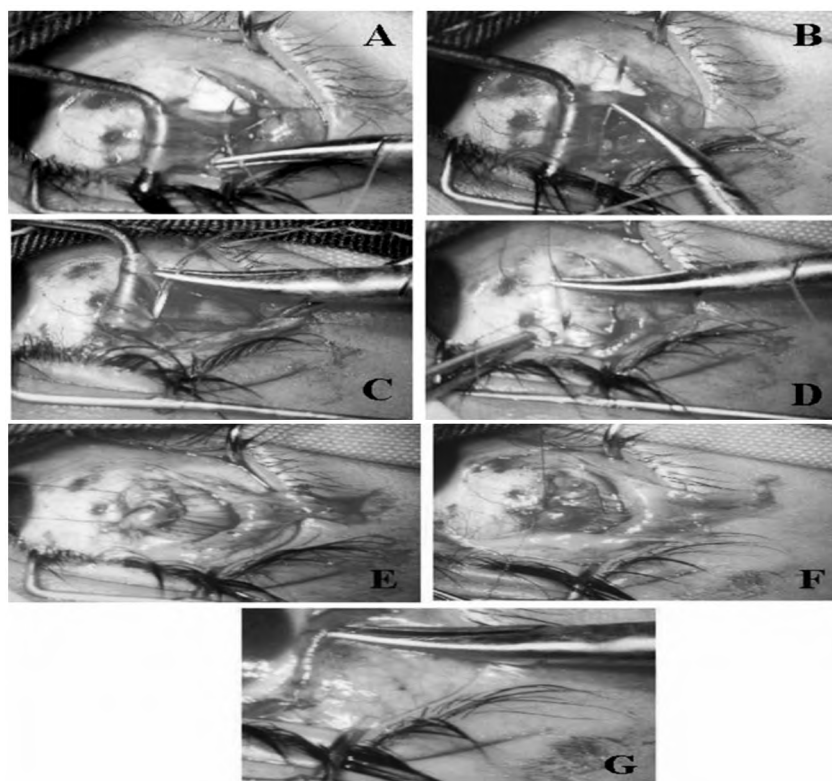


Fig. (1): Plication of a rectus muscle: (A) Partial thickness muscle suture. (B) Locking suture. (C) Partial thickness suture. (D) Sutures passing through insertion. (E) Pulling the muscle. (F) Tying the muscle to the insertion. (G) Closure of conjunctiva.

**Resection:**

Resection was done according to the standard technique using single suture and limbal approach, as described in the Color Atlas of Strabismus Surgery. The conjunctiva is exposed and the muscle is dissected as described before in steps 1-7 in tucking. Calipers are placed at the intended site of resection, and a security knot is placed in the centre of the muscle belly. 6/0 vicryl double armed suture was used for securing the central 2mm of the muscle (half muscle thickness).

One of the needles connected to the security knot is passed at half muscle thickness; this pass extends split thickness until it exits at the muscle edge. A full thickness locking bite is then placed through 2mm of the muscle edge. This is repeated with the other end of the suture. The muscle is excised anterior to the sutures.

The muscle stump is removed close to the sclera. The muscle is secured to the original insertion with deep scleral bites. The muscle is advanced to the scleral insertion by gently pulling on the suture, the sutured are tied using a double throw overhand knot. The conjunctiva is closed using interrupted inverted 8/0 vicryl sutures.

**Recession:**

The conjunctiva is exposed and the muscle is dissected as described before in steps 1-7 in tucking and resection. Two 6/0 vicryl sutures are passed through the outer quarters of the muscle tendon near the insertion. The muscle tendon is disinserted from the sclera with the help of tenotomy scissors. The amount of recession is measured with the calipers and marked on the sclera. The muscle tendon is sutured with the sclera at the marked site posterior to original insertion. Conjunctival flap is sutured back using 8/0 vicryl sutures.

**Post-operative management:**

Post-operative medications included a combination of antibiotic/steroid eye drops four times daily and antibiotic/steroid eye ointment by night. The eye patch was removed in the first dressing of the patient, first day post-operative.

**Follow-up:**

The patients were seen post-operatively on first day, one week, one month, and three months following surgery. In the follow-up visits, the post-operative alignment was evaluated using prism and cover test.

**Statistical analysis:**

Data was collected & analyzed using Statistical Package for Social Sciences (SPSS) program.

**Results**

This study was carried out in Ophthalmology Department at Aswan University Hospital in the period from Febraury 2019 to Febraury 2020. Forty patients were enrolled in this study, their ages ranged from 4 to 44 years with a mean of 17.58 ± 11.59 SD. 23 patients were males (57%) and 17 were females (42.5%).

*Patients were divided into two groups:*

- **Group I:** Included 20 patients (10 male & 10 female) who had MR plication with LR recession.
- **Group II:** Included 20 patients (13 male & 7 female) who had MR resection with LR recession.

Table (1): Results of plication and resection groups.

(Whole group)	Mean	SD	Range	Median (IQR)
• Angle (pre-operative) (PD)	60.63	17.40	(35-100)	60 (45-75)
• Angle (post-operative) (PD)	9.23	8.23	(4-30)	6 (4-10)
• Amount of (LR) recession (mm)	7.9	0.5	(6-9)	8 (8-8)
• Amount of (MR) plication (mm)	6.05	0.51	(5-8)	6 (6-6)
• Amount of (MR) resection (mm)	5.9	0.31	(5-6)	6 (6-6)

Table (2): Comparison between refractive state in 2 operation groups.

SE	Group		Chi-Square test of sig.	
	Plication group N (%) Median (IQR)	Resection group N (%) Median (IQR)	p-value	Sig.
Hypermetrope	14 (70%)	12 (60%)	0.507	NS
Myope	6 (30%)	8 (40%)		

This table shows no statistical significant difference (*p*-value >0.05) between the 2 operation groups as regard refractive state.

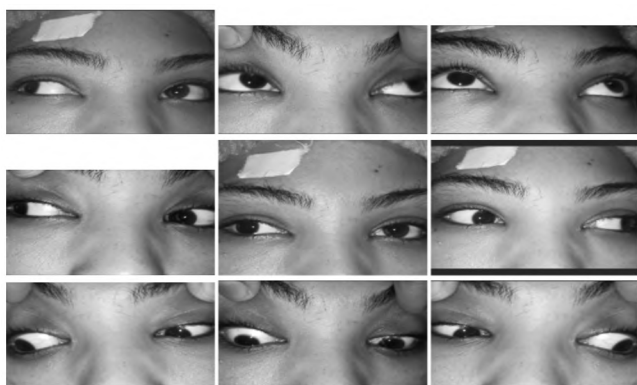
Desired alignment was considered to be achieving post-operative alignment ± 10 PD and under-correction or overcorrection was considered as post-operative angles more or less than 10 PD. A success rate of 85% was achieved in both groups, as the mean of post-operative angle was 9.55 ± 8.98 for plication group and 8.9 ± 7.62 for resection group.

Table (3): Comparison between 2 operation groups as regard correction.

Correction	Group		Fisher's Exact test	
	Plication group	Resection group	P-value	Sig.
	Mean ± SD N (%)	Mean ± SD N (%)		
Straight eye	17 (85%)	17 (85%)	1.00(F)	NS
Under correction	3 (15%)	3 (15%)		

(F): Fisher's Exact test of significance.

This table shows no statistical significant difference ( $p$ -value  $>0.05$ ) between the 2 operation groups as regard post-operative correction.



(A)

Table (4): Comparison between plication & resection as regard surgical time for each procedure.

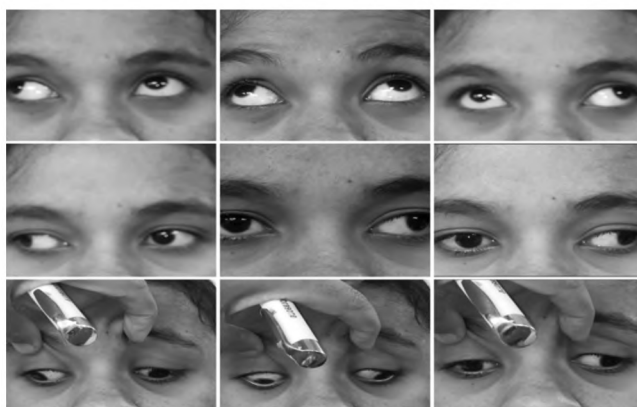Surgical time (minutes)	Group				Student t-test	
	Plication group		Resection group		P-value	Sig.
	Mean	SD	Mean	SD		
	29.3	2.62	35.1	2.27	<0.001	S

This table shows highly statistical significant difference ( $p$ -value  $<0.001$ ) between the 2 operation groups as regard operation time.

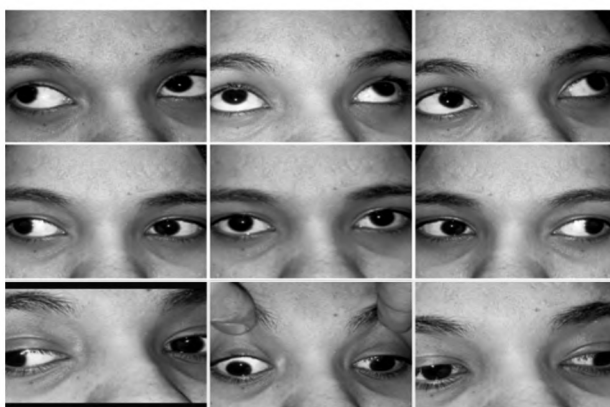

(B)

Fig. (2): RT XT (80 PD); (A) Before surgery. (B) After BLR + RT MR plication (corrected).

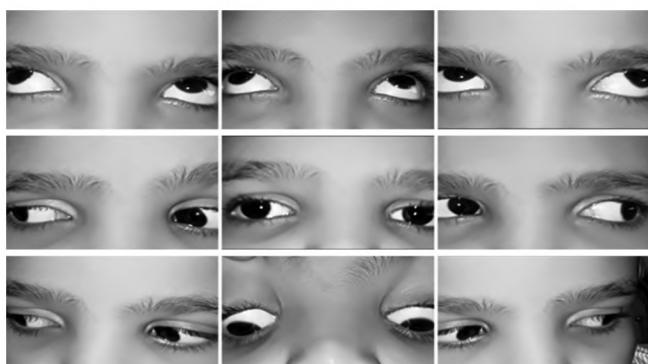

(A)

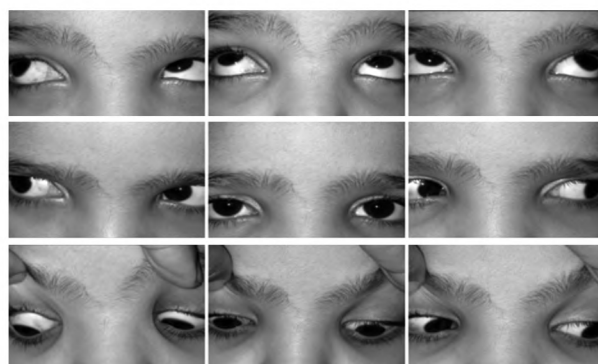


(B)

Fig. (3): LT XT (80 PD); (A) Before surgery. (B) After BLR + LT MR plication (under corrected).



(A)



(B)

Fig. (4): RT XT (50 PD); (A) Before surgery. (B) After RT LR recession + MR plication (corrected).

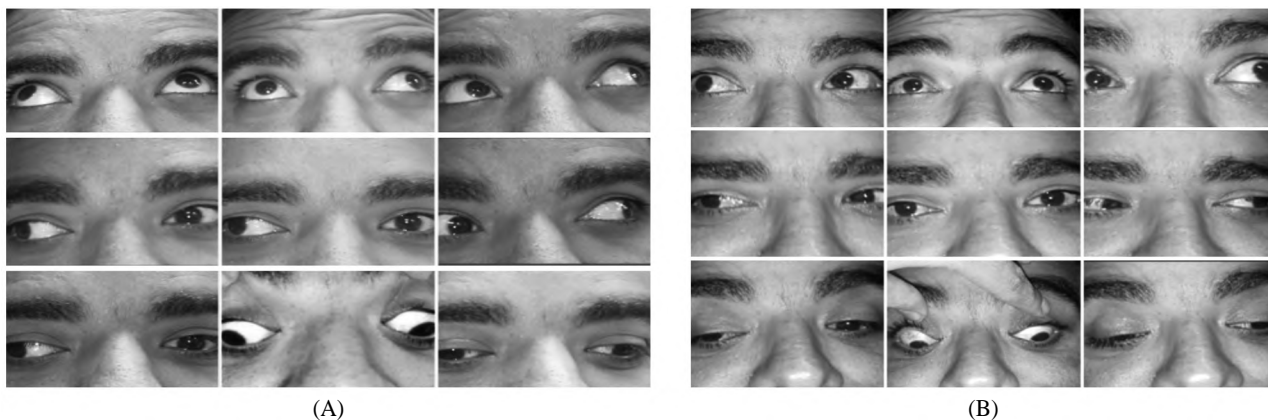

Fig. (5): RT XT (85 PD); (A) Before surgery. (B) After BLR + RT MR plication (undercorrected).

*The post-operative lump in plication procedure:*

In all cases of plication, the lump completely disappeared after (4 to 6 weeks) of follow-up, only leaving a conjunctival scar that was not different from that found in cases of resection.

Only one case had a post-operative granuloma in the plication group at the site of LR recession after 3 weeks of surgery that did not respond to medical treatment for two weeks and surgical evacuation needed. Two weeks after excision, the granuloma completely disappeared.

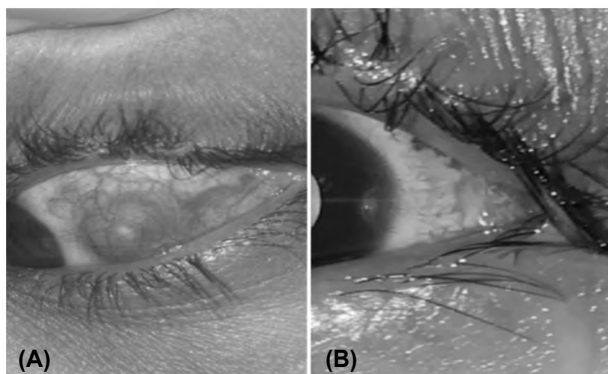


Fig. (6): (A) Post-operative granuloma at the recession site that developed 3 weeks after surgery in plication group. (B) 10 days after excision, the granuloma completely disappeared.

**Discussion**

The study focus was intended to compare between two different muscle strengthening techniques. This study included all patient with exotropia elder than four years old and patients who had been previously operated and those with restrictive strabismus were excluded. Ages of patients ranged from 4 to 44 years old with mean of 17.58 ± 11.59 SD. This study included 40 patients (23 male & 17 female), 20 patients underwent reses-

sion/plication (R & P) and the other 20 patients underwent recession/resection (R & R).

The pre-operative angle of deviation ranged from 35-100 (PD). The mean amount of LR recession was 8±0.33 SD in plication group compared to 7.8±0.5 SD in resection group. The mean amount of MR plication was 6.05±0.51 SD compared to 5.9±0.31SD for resection.

We used 6/0 vicryl sutures for recession and resection and 5/0 ethibond sutures for plication. Compared to the study performed by Neugebauer and associates in 1997, they used 6/0 vicryl for plication, like the current, they did not mention any effects on the stability of the results.

This study found that, the plication procedure is relatively of shorter surgical time than the standard resection as the mean operative time was 29.3 ± 2.62 for plication and 35.1 ± 2.27 for resection. This fact was mentioned by Olitsky, et al. [3].

A success rate of 85% was achieved in both groups, there were 6 cases of under correction (3 cases in each group). The explanation of the two undercorrected cases with large postoperative angle of deviation (30 PD), is that both cases had a poor vision that may affected the preoperative measurement of angle of deviation and/or post-operative poor fixation. Only one case of overcorrection with post-operative esotropia (15 PD) was found in plication group that became with straight eye after one month of follow-up.

Chaudhuri and Demer [2], compared the surgical outcomes of resection and plication. Like us, they found no significant differences in the post-operative outcomes between patient plicated or resected. The study included 53 patients (31 male and 22 female), 31 patient shad resection and 22 patient had plication. Their follow-up periods were

longer with resection group: A mean of 1243 days, compared to a mean of 137 days for plication group. Compared to their study, admittedly, our patients are fewer: 40 overall as compared to 53 of Chaudhuri and Demer's, although the number underwent plications was better matched: 20 in ours compared to 22 in theirs. Our cases were on average younger:  $17 \pm 11$  years as compared to 38 years in their study. Unlike our study that included only patient with exotropia, their study included esotropic and exotropic patients. Also, they included reoperations in their study, whereas we excluded such patients.

Also, Kimura and Kimura [4], compared the surgical outcomes of plication and resection in adult patients with exotropia. Forty-five patients underwent PR and 43 underwent RR. There was no difference between PR and RR at 12 months (R & P 67%; R & R 60%). Compared to our study included all patients older than 4 years old, Kimura's study included only adult patients. The pre-operative deviation in Kimura's study was ( $40.1 \pm 12.9$  PD in the P & R group and  $40.0 \pm 14.9$  PD in the R & R group) was of lesser amount as compared to our study ( $62.25 \pm 17.36$  PD in the P & R group and  $59 \pm 17.74$  PD in the R & R group); therefore, the amount of muscle plicated, resected, and recessed was also of lesser amount in their study as compared to ours.

However, Al-Kharashi and Hunter [5], found that surgical success was significantly higher in the resection group than in the plication group (89% vs. 58%). This study included 72 patients, 48 underwent resection and 24 underwent plication. The mean final follow-up of  $19 \pm 13$  months (range, 3-56 months). Unlike our study, they included both vertical and horizontal types of strabismus in their study which may had contributed to that difference in result between the plication and resection groups.

The post-operative lump completely disappeared after (4 to 6 weeks) leaving just a conjunctival scar that was not different from that found in cases of resection. This agreed with the reported

literature by Wright 6 that stated that the lump flattened over 6 weeks.

There was a case of post-operative granuloma that developed at the site of LR recession in the plication group after 3 weeks of surgery that did not respond to medical treatment for two weeks and surgical excision finally needed after five weeks from surgery. Espinosa and Lueder 7 reported that conjunctival pyogenic granulomas are a potential complication of strabismus surgery (2.1%).

Although the current study did not focus on the effect of both surgical techniques on anterior ciliary circulation, no signs of ASI were found in the two operation groups after surgery, as we did not operate on more than two muscles in the same eye.

### References

- 1- VON NOORDEN G.K.: Principles of surgical treatment, vision and binocular ocular motility: Theory and management of strabismus 4th ed. Mosby, 479-536, 1990.
- 2- CHAUDHURI Z. and DEMER J.L.: Surgical outcomes following rectus muscle plication: A potentially reversible, vessel-sparing alternative to resection. *JAMA Ophthalmol.*, 132: 579-85, 2014.
- 3- OLITSKY S.E., KELLY C.J., LEE H. and NELSON L.B.: Unilateral rectus resection in the treatment of undercorrected or recurrent strabismus. *J. Pediatr. Ophthalmol. Strabismus.*, 38: 349-53, 2001.
- 4- KIMURA Y. and KIMURA T.: Comparative study of plication-recession versus resection-recession in unilateral surgery for intermittent exotropia. *Jpn. J. Ophthalmol.*, May, 61 (3): 286-91, 2017.
- 5- ALKHARASHI M.S. and HUNTER D.G.: Outcome of ocular alignment following rectus muscle plication compared to resection JAAPOS. August, Volum 20, Issue 4, Page e1, 2016.
- 6- WRIGHT K.W.: Rectus tightening procedures. *Color Atlas of strabismus surgery strategies and techniques.* 2nd ed. Ed. Bosnall L.B. & Kiss T. Panama: J.P. Lippincott, 113-21, 2000.
- 7- ESPONZA G.M. and LUEDER G.T.: Conjunctival pyogenic granulomas after strabismus surgery, 112 (7): 1283-6, 2005.

## دراسة مقارنة بين طريقة إستئصال جزء من العضلة المستقيمة الأنسية وطريقة ثنى العضلة عند إقترانها مع إرخاء العضلة الجانبية فى علاج الحول الوحشى

يعد ربط وثنى العضلات المستقيمة طريقة بديلة فعالة وسهلة لإستئصال جزء من العضلة فى علاج حالات الحول.

تهدف هذه الطريقة أساساً لوقاية الأوعية الهدبية الأمامية مما يقلل نسبة حدوث قصور الإمداد الدموى للجزء الأمامى من العين. كما تعد طريقة آمنة لمنع حدوث فقدان العضلة.

تهدف هذه الدراسة لمقارنة طريقة ربط العضلات لإستئصال جزء من فعاليتها وطريقة إستئصال جزء من العضلة من ناحية الفعالية وثبات النتائج والأمان وإمكانية توقع النتائج والمضاعفات.

تكونت الدراسة من أربعين مريضاً تم تقسيمهم إلى مجموعتين:

المجموعة الأولى تكونت من عشرين مريض تم عمل ربط للعضلات لهم والمجموعة الثانية تكونت من عشرين مريض تم عمل إستئصال لجزء من العضلة لهم. وقد تم إجراء فحص شامل لجميع المرضى بما فيهم إنكسار العين وفحص قاع العين وقيا س درجة الحول وحدة الإبصار وحركة عضلات العين.

تم تقييم النتائج عند مرور أسبوع وشهر وثلاث أشهر من تاريخ إجراء الجراحة.

كانت نسبة النجاح للمجموعتين بعد متابعة لمدة ثلاث أشهر متساوية إذ أنها كانت ٨٥% فى المجموعتين. كما أثبتت الدراسة أن النتائج كانت ثابتة على مدار الفترة الزمنية فى المجموعتين.

وقد أثبتت الدراسة أن نتائج العملية لما تتأثر بسن المريض أو زاوية الحول قبل العملية أو مقدار إنكسار العين فى كلتا المجموعتين.