

## Percutaneous Transforaminal Endoscopic Lumbar Discectomy in Adolescents

IHAB A.M. HOSNY, M.D.

The Department of Orthopedic Surgery, Armed Forces Collage of Medicine, Cairo, Egypt

### Abstract

**Background:** Lumbar disc herniation in adolescents is relatively rare but poses a serious problem to the patient and the parents. Percutaneous Transforaminal Endoscopic Lumbar Discectomy (PTELD) has several advantages over conventional surgeries because it decreases perioperative complications and increases favorable clinical outcomes.

**Aim of Study :** The aim of this study is to evaluate the clinical outcomes of PTELD in adolescent patients.

**Patients and Methods:** Adolescence is defined as any person whose age is between 10 and 19 years. This was a retrospective study which included 14 patients aged between 15 and 19 years treated by PTELD for low back pain and sciatica. Clinical and functional outcomes were evaluated using visual analogue scale (VAS), Oswestry Disability Index (ODI) and follow-up at 2 weeks, 1, 2, 6 and 12 months postoperatively. Final results were assessed using the modified MacNab score. All surgeries were done by the same surgeon.

**Results:** Overall there was improvement of clinical and functional outcomes during the postoperative follow-up evaluation. There were no immediate perioperative complications, such as infection, nerve injury or dural tears but only two patients developed dysaesthesia and were treated medically. There was no recurrence of herniations as the patients followed a strict postoperative rehabilitation program.

**Conclusion:** PTELD is a minimally invasive technique which is effective and safe for adolescent patients. PTELD decreases the post-operative morbidity and permits faster mobility and rehabilitation.

**Key Words:** Transformational – Endoscopic – Discectomy – Adolescents – Lumbar disc herniation.

### Introduction

**LUMBAR** disc herniation (LDH) is a relatively rare disorder in adolescents compared to adults [1]. Where in adults chronic degenerative changes are the main cause, the main causes of LDH in adoles-

cents are trauma with subsequent axial load or a sport related injury [2,3,4].

Patients with lumbar disc disease commonly suffer from low back pain and lower extremity radiculopathy. A significant number of patients may only have radicular symptoms [5]. However LDH being rare in adolescents can lead to a relative delay in establishing the diagnosis and ineffective courses of treatment. Awareness of LDH in adolescents will help in taking a relevant medical history, perform a directed physical examination and order appropriate imaging studies [1]. This will aid in initiating appropriate management plans, be it conservative or operative for achieving a favorable outcome.

Percutaneous Transforaminal Endoscopic Lumbar Discectomy (PTELD) has been developed as a minimally invasive spinal surgery for soft disc herniation. PTELD provides some benefits over open discectomy, such as less damage to paraspinal soft tissue, shorter hospital stays, and earlier return to work [7].

### Epidemiology:

The occurrence of LDH in adolescents is usually supposed to be less than that in adults. Relevant studies have shown that adolescents represent only 0.5% to 6.8% of all patients hospitalized for LDH [2]. Generally lumbar disc herniation occurs rarely during the first decade of life. However the literature shows that most adolescents with complaints related to LDH haven't been examined properly and diagnosed until the age of 15 years [8].

There is no evident gender predominance of disk herniation in adolescent population. Some studies have shown a female predominance, although some other series have found a slight male predominance [1].

**Correspondence to:** Dr. Ihab A.M. Hosny, The Department of Orthopedic Surgery, Armed Forces Collage of Medicine, Cairo, Egypt

*Etiology:*

The possible causes of adolescent LDH include: Trauma, especially from sport injuries as the main cause, ranging between 30% to 60% of adolescents with symptomatic LDH. Excessive or repetitive axial loading, improper technique, heavy lifting are also highly related to this condition [3,5]. Additionally genetic factors are documented as a common source of adolescent LDH. Studies have shown that between 13 and 57% of adolescents with LDH have a first-degree relative with the same disorder [2,3].

*Pathophysiology:*

The disc level distribution in adolescents is similar to that seen in adults. The L4-L5 and L5-S1 levels are affected in over 50% of all disc herniations [1]. Compared with adults, pathological studies of herniated disks in adolescents show more elastic consistency with high water content [1]. This leads to the less responsiveness to conservative treatment and require operative intervention. Studies have shown that underlying abnormalities can be also associated with lumbar disk herniation including occult spina bifida, extra lumbar vertebra, sacralization of the fifth lumbar vertebra, spinal and lateral recess stenosis and spondylolisthesis [9].

Due to the low incidence of the condition in this age group as compared to adults, it increases the duration for correct diagnosis (10 months) as compared with adult patients (4.7 months) [1].

This study was performed to evaluate the outcomes of PTELD in adolescent patients.

**Patients and Methods**

Adolescence is a transitional phase of growth and development between childhood and adulthood. The world health organization defines an adolescent as any person between ages 10 and 19.

A retrospective study including a total of 14 adolescent patients who underwent PTELD between January 2017 and December 2019 in Helmia and Galaa Military Hospitals.

*Inclusion criteria:*

- 1- Patients aged 10 to 19 years.
- 2- Patients with low back pain and sciatica due to LDH where conservative treatment has failed for 6 weeks.
- 3- Patients with lumbar disc herniations and neurologic deficits.

- 4- Recent dynamic plain X-rays and MRI scan of lumbar spine revealed disc herniation without instability correlating with clinical presentation.
- 5- Positive root tension sign (Straight leg raising test).

*Exclusion criteria:*

- 1- Patients of lumbar canal stenosis.
- 2- Cases due to other pathologic conditions (fracture, trauma, tumor, infection).
- 3- Cases with complete disc collapse.
- 4- Cases of spinal instability.
- 5- Foraminal spur or bony compression.
- 6- Cases which did not complete the follow-up.

Clinical outcomes were assessed using the visual analogue scale (VAS; 0-10, with 0 = no pain), and functional outcomes were scored according to the Oswestry Disability Index (ODI; 0-100%), and final results were assessed using the modified MacNab score. Follow-up was done at 2 weeks, 1, 2, 6 and 12 months postoperatively. All surgeries were done by the same surgeon.

Additionally operating time, length of hospital stay, and perioperative complications were evaluated.

After Ethical committee approval, all patients and their guardian signed an informed and detailed consent before any procedure.

*Statistical methods:*

Data were statistically analyzed using statistical software SPSS 22.0. All results were expressed as mean  $\pm$  standard deviation ( $x \pm SD$ ). The obtained data were processed by statistical analysis and evaluated using *t*-test.  $p < 0.05$  was considered statistically significant.

*Operative technique:*

All patients received 1 gm third generation cephalosporin intravenously as antibiotic prophylaxis; they were placed on a radiolucent table in the prone position with the knees flexed. Anteroposterior (AP) and lateral views were taken before needling; this was to avoid radiographic error and malposition of the needle, cannula and endoscope. All procedures were done under local anesthesia with monitoring and additional sedation was used when needed.

*Marking the entry point:* Using a radio opaque rod, the entry point was marked with a permanent marker using AP and lateral views. The entry point is usually 10 to 14cm from the midline.

*Needling:* All the lumbar area was painted with iodine and draping was done wide enough. Skin, fascia, muscles were infiltrated with 1% lidocaine. Proper endoscopic view targeting the fragment depends on the initial placement of the needle. The needle entry point typically starts about 10 to 14cm from the midline. To optimize the approach to access the specific herniation type, the entry point can be a little more medial (for foraminal or extra-foraminal discs) or lateral (for central and some paracentral disc). An 18 gauge aspiration needle (21 inch length) was inserted from the entry point at a trajectory (15-20 degree to the floor) to hit the lateral facet, then slid ventral to the facet using the facet as a lever arm. The needle was advanced to land in the foramen at the medial pedicular line in the AP view and at the posterior vertebral line in the lateral view and then the needle was advanced into the disc to be in the midline in AP view and in the posterior quadrant in the lateral view. The stylet of the needle was removed, a guide wire was passed through the needle into the disc space and the needle removed.

Skin was incised at the entry point for an 8mm length; the dilator was passed over the guide wire to reach the posterior annulus. Local anesthetic was given by using the side channel of the dilator. The guide wire was removed and the dilator was

gently hammered into the disc. Using the image intensifier the position of the dilator was checked to make sure that it was in the posterior quadrant of the disc in the lateral view and central in the AP view. The operation sheath was inserted over the dilator, then the dilator was removed and the endoscope was inserted through the operation sheath.

Most of the cases were operated by in-out technique but sometimes we used half-half technique, the disc was seen directly and the fragment was removed. Bleeding control was done by continuous washing during procedure and by bipolar cautery. Before removing the endoscope, we also routinely visualized and confirmed the pulsations of the dura, traversing and exiting nerve roots, also the patient was asked to cough to see the free movement of the disc tear flaps which confirms the adequacy of the decompression. Once discectomy was finished, the endoscope and operative sheath were removed.

*Post-operatively:* All Patients were allowed to ambulate on the same post-operative day as soon as they can independently walk and discharged within 24 hours. Post-operative oral antibiotics and analgesics are given for 3-7 days following surgery.

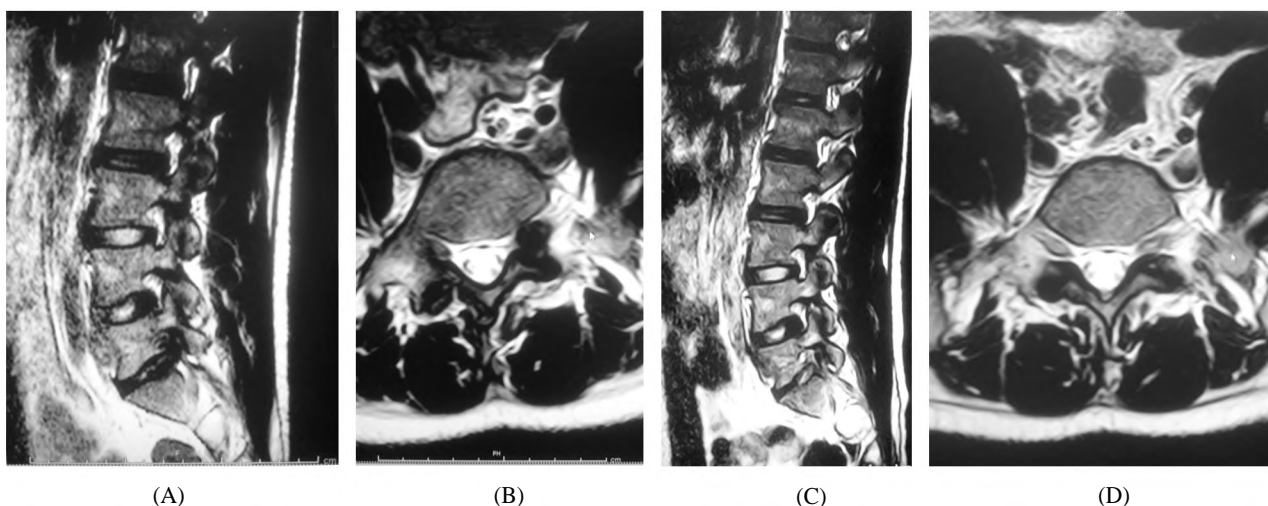


Fig. (1): (A,B) Pre-operative and (C,D) Post-operative MRI of a 19 year old military cadet with L5-S1 foraminal disc herniation.

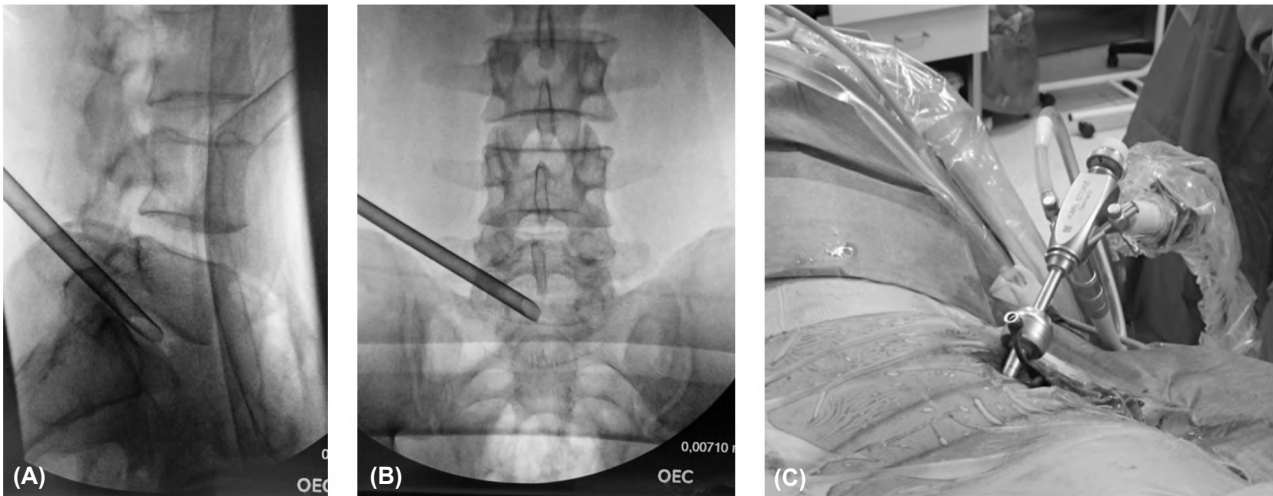


Fig. (2): (A) Sheath in posterior quadrant in lateral view and (B) central in AP view and (C) endoscope inserted through the sheath.

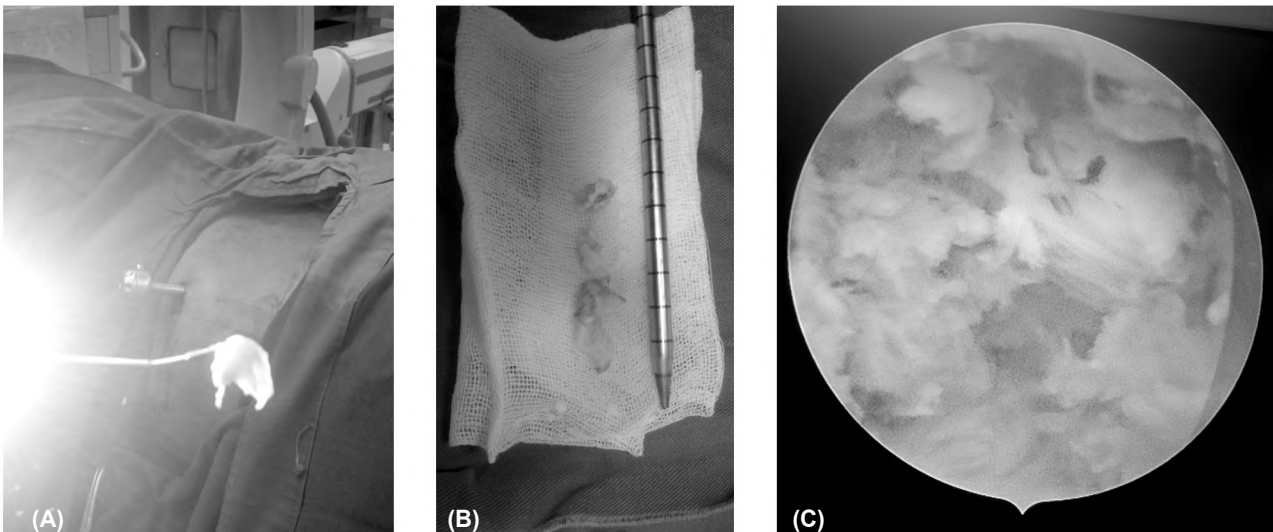


Fig. (3): (A,B) Showing fragment removed and (C) Traversing nerve root after fragment removal.

### Results

The 14 patients were 11 males (78.5%) and 3 females (21.5%), 5 aged 19 years, 5 aged 18 years, 3 aged 16 years and 1 aged 15 years with a mean of 17.71 years. The radicular pain was on the right side in 8 patients, on the left in 5 patients and bilateral in 1 case. The herniation level was L1-2 in 1 patient and L4-5 in 3 patients, L5-S 1 in 8 patients and both L4-5 and L5-S 1 in 2 patients. Two patient 1male and 1 female both aged 16 years were professional hand ball players, 3 were cadets in different military colleges, 2 trained regularly and 2 had a specific traumatic incident which adds up to 64% traumatic or sports related causes.

One patient aged 16 years was bilateral and had weakness of feet dorsiflexion, left grade 2 and right grade 3. Both feet improved one grade imme-

diately postoperative, the right foot became normal at 2 weeks and the left at 2 months.

Two patients were double level L4-5 and L5-S 1. The first is a female 19 years. During her surgery we injected radio opaque dye into the disc to show the fragments and leak also to increase the intradiscal pressure which is a provocative test that resulted in an increase in radicular pain at both levels. The second was a male 19 years military cadet who had an L5-S 1 herniation which was removed endoscopically and an L4-5 annular tear which was injected with corticosteroid. Five months later a herniation developed through the L4-5 tear and had to be removed endoscopically.

One male patient aged 19 years had a very high iliac crest and a transiliac approach was used as the fragment was large and central at L5-S 1.

The operation time ranged from 40 to 90 minutes with average of 60 minutes. Blood loss was 10 to 20ml.

Straight leg raising improved to more than 80 degrees immediately postoperative in 11 patients and 70 degrees in 3 patients and became 90 degrees in all patients at 2 months.

There were no complications postoperatively such as infection, dural tears or nerve injury, 2 patients developed dysaesthesia which disappeared with medical treatment in 4 weeks time.

All patients left the hospital the next day following surgery.

All patients returned to normal activity in 6 to 8 weeks and started sports training in 10 to 12 weeks and back to professional playing in 14 to 16 weeks.

Table (1): Summary of patients' demographics and clinical characteristics.

Item	No.
Number of patient	14
Gender (males/females)	11/3
Average age (years)	17.71
<i>Side:</i>	
Right	8
Left	5
Bilateral	1
<i>Discectomy level:</i>	
L1-2	16
L4-5	1
L5-S 1	3
L4-5 + L5-S 1	8
Trauma or exercise and sports as a cause	2
	9

Table (2): Summary of VAS scores of limb pain and ODI scores.

Item	VAS scores ( $\bar{x} \pm S$ )	ODI cores ( $\bar{x} \pm S$ )
Before Surgery	7.08±1.12	68.4±10.5
Immediate Post operation	3.23±1.01	19.8±9.7
2 weeks	3.0±1.01	12.1±8.2
1 month	2.62±0.51	10.4±9.6
2 months	2.31±0.48	9.7±6.7
6 months	1.46±0.52	6.5±4.3
1 year	1.0±1.2	5.3±3.3

The leg pain VAS scores and ODI scores were significantly improved after operation compared with those before operation ( $p < 0.01$ ), and the difference was statistically significant (Table 2). At the last follow-up, the modified MacNab score was excellent in 10 cases, good in 3 cases, fair in 1 case, and the excellent and good rate was 92.8%.

## Discussion

In 1975, Hijikata et al. [10] reported the use of percutaneous lumbar discectomy in the treatment of adult LDH. Introduction of new techniques, scopes, and instruments overcame some of the technical limitations and increased the spectrum of indications for PTELD.

The minimal traumatic nature of PTELD decreases the perioperative complications such as infection, wound complications, bleeding, nerve injury and dural tears. Another benefit of PTELD over microdiscectomy is that the entire procedure can be performed through a minimal skin incision under local anesthesia [11]. This allows communication with the patient all through the surgery and confirms the outcome during the surgery itself.

PTELD is a better minimally invasive surgical method, compared with fenestration discectomy (FD), with such advantages as less trauma, less blood loss, early function recovery, less effect on lumbar spinal stability. It is a safe and effective minimally invasive technique for adolescent lumbar disc herniation and the outcomes of PTELD are similar to that of FD and microdiscectomy [12-14].

LDH is a common and frequently occurring disease of the spine and is the most common cause of low back pain and sciatica. In recent years, due to the lifestyle changes of people, the prevalence of LDH has gradually increased in adolescents [15]. Studies have shown that adolescents represent only 0.5% to 6.8% of all patients hospitalized for LDH [2]. The main pathogenesis includes genetic and developmental malformation, trauma and sports [2,3,5]. In the present study 64% of the causes were traumatic or sports related which correlates with the results of other published studies.

The recent advances in minimally invasive surgery has made percutaneous endoscopic discectomy (PED) techniques important procedures for the treatment of LDH in adults [16] but there are few published studies of PED in adolescent patients. To date, a few short-term studies with restricted sample size have shown success rates ranging from 91.3% to 100% [17,18,19]. Lee et al. [17] performed PED in 46 adolescents and reported a success rate of 91.3% and a recurrence rate of 2.2% (1 patient) at a mean follow-up duration of 37.2 months. Wang et al. [16] reported good outcomes in 25 adolescent patients, with a recurrence rate of 4%, but they did not report the duration of follow-up for these patients. In another study, Wang et al. [18] followed 29 patients for a mean duration of 20 months; excellent outcomes were shown in 93% patients,

and unfavorable symptoms were relieved through conservative therapy. Mayer et al. [20] reported a success rate of 100% in 4 cases with a mean follow-up of 2.8 years. Kurihara and Kataoka [21] reviewed 70 adolescents with disc herniation, only 40% of patients responded to conservative treatment, while recurrence of symptoms was common after returning to normal activity. Results after surgical discectomy were generally excellent. So when conservative treatment is ineffective, surgery is a better option.

The present study, although underpowered due to the rarity of LDH in adolescents, suggests adolescents might experience a quicker and better recovery course than adults after PTELD. The differences in leg pain VAS scores and ODI scores before and after the operation were statistically significant ( $p < 0.01$ ). According to the modified MacNab scale, the postoperative excellent and good rate was 92.8% which is comparable to the other published results. The above results suggest that the short-term curative effect of this surgical procedure is significant and its postoperative recovery is rapid.

In this study the adequacy of the disc decompression was judged during surgery by nerve root and dural pulsations and the free movement of the disc tear flaps when the patient is asked to cough. After the removal of the lumbar disc herniation, the healing of the annulus needs a relatively stable internal environment. The intervertebral disc in adolescents is usually hydrated, rubbery, and viscous [17] which may predispose to a high recurrence incidence of 20%-30% which was previously observed in this age group [5,18]. Premature lumbar bending and load-bearing will lead to the recurrence of the lumbar disc herniation. Delayed return to physical activities might help prevent excessive mobility of the spine and decrease downward pressure on the disc before the annulus ring heals [22]. In the present study we had no recurrences as the patients followed a strict rehabilitation program of back strengthening exercises and avoided excessive activity within the first 3 months after the operation.

PTELD can keep the stability of the spine of adolescent patients with lumbar disc herniation and prevent postoperative instability and lumbosacral pain caused by removal of lamina and part of articular process bone in traditional operation which is especially important for young patients and a good indication for long-term curative effect [12].

*This study is subject to several limitations:*

- 1- Lack of a none surgically treated group.
- 2- Lack of long term follow-up.
- 3- Single center design with limited sample size.

Long-term multicenter studies with large sample sizes are warranted to analyze the effectiveness of PTELD in the adolescent population.

*Conclusion:*

PTELD is a minimally invasive procedure which is safe and effective for the treatment of LDH in adolescents, with results that are comparable or may be even better than those achieved with microdiscectomy and conventional open surgery; also adolescents may have better outcomes than adults treated with PTELD. A good surgical technique and a strict postoperative rehabilitation program will give excellent results.

### References

- 1- JONATHAN R.S., JOHN M.K., MISLOW, ARTHUR L.D. and MARK R.P.: Pediatric disk disease. *Neurosurg clin N. Am.*, 18: 659-667, 2007.
- 2- DANG L., CHEN Z., LIU X., GUO Z., QI Q., LI W., et al.: Lumbar Disk Herniation in Children and Adolescents: The Significance of Configurations of the Lumbar Spine, *Neurosurgery*, 77: 954-959, 2015.
- 3- DANG L. and LIU Z.: A review of current treatment for lumbar disc herniation in children and adolescents, *Eur. Spine J.*, 19: 205-214, 2010.
- 4- KUMAR R., KUMAR V., DAS N.K., BEHARI S. and MAHAPATRA A.K.: Adolescent lumbar disc disease: Findings and outcome, *Childs Nerv. Syst.*, 23: 1295-1299, 2007.
- 5- LAVELLE W.F., BIANCO A., MASON R., BETZ R.R. and ALBANESE S.A.: Pediatric Disk Herniation. *J. Am. Acad. Orthop. Surg.*, 19: 649-656, 2011.
- 6- MAROON J.C.: Current concepts in minimally invasive discectomy. *Neurosurgery*, 51 (5 Suppl): S137-145.6, 2002.
- 7- YONG AHN: Endoscopic spine discectomy: Indications and outcomes *International Orthopaedics (SICOT)*, 43: 909-916, 2019.
- 8- KAVEH HADDADI: Pediatric Lumbar Disc Herniation: A review of manifestations, diagnosis and management. *J. Pediatr. Rev.*, 4: e4725, 2016.
- 9- SIRIWARDENA K.M.D.L.: Literature Review of Pediatric lumbar disk herniation, 4 (4): 1075, 2018.
- 10- HIJIKATA S., YAMAGISHI M. and NAKAYMA T.: Percutaneous discectomy: A new treatment method for lumbar disc herniation. *J. Tokyo Den. Hosp.*, 5: 39-41, 1975.
- 11- RUETTEN S., KOMP M., MERK H. and GODOLIAS G.: Full-endoscopic interlaminar and transforaminal lumbar discectomy versus conventional microsurgical

- technique: A prospective, randomized, controlled study. *Spine (Phila Pa 1976)*, 33 (9): 931-939, 2008.
- 12- LI J., MA C., LI Y., LIU D.W., WANG D., DAI W., et al.: A Comparison of Results Between Percutaneous Transforaminal Endoscopic Discectomy and Fenestration Discectomy for Lumbar Disc Herniation in the Adolescents. *Zhonghua Yi Xue Za Zhi*, 95: 3852-3855, 2015.
- 13- LIU W., LI Q., LI Z., CHEN L., TIAN D. and JING J.: Clinical Efficacy of Percutaneous Transforaminal Endoscopic Discectomy in Treating Adolescent Lumbar Disc Herniation. *Medicine (Baltimore)*, 98: e14682, 2019.
- 14- CHEN Y., SONG R., HUANG W. and CHANG Z.: Percutaneous Endoscopic Discectomy in Adolescent Lumbar Disc Herniation: A 3- To 5-year Study. *J. Neurosurg Pediatr.*, 23: 251-258, 2018.
- 15- SMORGICK Y., FLOMAN Y., MILLGRAM M.A., ANEKSTEIN Y., PEKARSKY I. and MIROVSKY Y.: Mid- to longterm outcome of disc excision in adolescent disc herniation. *Spine J.*, 6: 380-4, 2006.
- 16- WANG H., CHENG J., XIAO H., LI C. and ZHOU Y.: Adolescent lumbar disc herniation: experience from a large minimally invasive treatment centre for lumbar degenerative disease in Chongqing, China. *Clin. Neurol. Neurosurg*, 115: 1415-1419, 2013.
- 17- LEE D.Y., AHN Y. and LEE S.H.: Percutaneous endoscopic lumbar discectomy for adolescent lumbar disc herniation: Surgical outcomes in 46 consecutive patients. *Mt Sinai J. Med.*, 73: 864-870, 2006.
- 18- WANG X., ZENG J., NIE H., CHEN G., LI Z., JIANG H., et al.: Percutaneous endoscopic interlaminar discectomy for pediatric lumbar disc herniation. *Childs Nerv. Syst.*, 30: 897-902, 2014.
- 19- MAYER H.M., MELLEROWICZ H. and DIHLMANN S.W.: Endoscopic discectomy in pediatric and juvenile lumbar disc herniations. *J. Pediatr. Orthop. B*, 5: 39-43, 1996.
- 20- MAYER H.M., MELLEROWICZ H. and DIHLMANN S.W.: Endoscopic discectomy in pediatric and juvenile lumbar disc herniations. *J. Pediatr. Orthop. B*, 5: 39-43, 1996.
- 21- KURIHARA A. and KATAOKA O.: Lumbar disc herniation in children and adolescents. A review 10 of 70 operated cases and their minimum 5-year follow-up studies. *Spine*, 5: 443-451, 1980.
- 22- LAGERBÄCK T., ELKAN P., MÖLLER H., GRAUERS A., DIARBAKERLI E. and GERDHEM P.: An observational study on the outcome after surgery for lumbar disc herniation in adolescents compared with adults based on the Swedish Spine Register. *Spine J.*, 15: 1241-1247, 2015.

## استئصال الإنزلاق الغضروفي القطني بمنظار الثقب العصبى عن طريق الجلد فى المراهقين

الخلفية: يعتبر الإنزلاق الغضروفي القطني فى المراهقين نادرسياً ولكنه يسبب مشكلة كبيرة للمريض وذويه. يتميز إستئصال الإنزلاق الغضروفي القطني بمنظار الثقب العصبى عن طريق الجلد PTELD بمزايا كثيرة عن الجراحات التقليدية حيث أنه يقلل المضاعفات المحيطة بالجراحة ويزيد من النتائج الإكلينيكية المواتية.

الهدف من الدراسة: الهدف من هذه الدراسة هو تقييم النتائج الإكلينيكية لإستئصال الإنزلاق الغضروفي القطني بمنظار الثقب العصبى عن طريق الجلد فى المراهقين.

الطرق والمرضى: تعرف المراهقة بأنها أى الشخص عمره بين ١٠ و ١٩ سنة. تضمنت دراستنا ١٤ مريض سنهم بين ١٥ و ١٩ سنة. تم علاجهم بواسطة PTELD لألم أسفل الظهر وتوتر العصب الوركى الناجم عن الإنزلاق الغضروفي القطني. قيمت النتائج الإكلينيكية والوظيفية باستخدام المقياس التناظري البصرى (VAS) ومؤشر الإعاقة (ODI) Oswestry والمتابعة فى ٢ أسبوع و ١٢، ٦، ٢، ١ شهراً بعد الجراحة. تم تقييم النتائج النهائية باستخدام مؤشر مكناب المعدل. Modified Macnab أجريت جميع العمليات الجراحية بواسطة نفس الجراح.

النتائج: النتائج الإكلينيكية والوظيفية تحسنت خلال تقييم المتابعة بعد الجراحة. لم تكن هناك أى مضاعفات أثناء أو بعد الجراحة مباشرة، مثل الإلتهاب الميكروبي للجرح أو إصابة الأعصاب أو قطع للأ م الجافية ولكن حدث إلتهاب لأعصاب فى إثنان من المرضى وتم علاجهم بعلاج دوائى. لم يكن هناك أى حالات إرتجاع للإنزلاق الغضروفي نظراً لإتباع المرضى لبرنامج تأهيل صارم بعد العملية.

خاتمة: PTELD هى تقنية ذات تدخل جراحى محدود فعالة وآمنة للمراهقين. يقلل PTELD من معدلات الاعتلال بعد الجراحة ويسمح بحركة وإعادة تأهيل أسرع.