

Short Term Outcomes of Laparoscopic Ventral Approach of Rectopexy with Polypropylene Mesh for Rectal Prolapse

AYMAN M. ESSAWY, M.D.; AHMED E. FARES, M.D.; ASHRAF M. THABET, M.D. and
KHALED M. BAUOMIE, M.D.

The Department of General Surgery, Faculty of Medicine, Fayoum University

Abstract

Background: Complete rectal prolapse (CRP) is circumferential herniation of all layers of the rectum through the anal sphincter. Patients with CRP may suffer from a long history of constipation, which precedes the prolapse. Surgical correction is the main treatment of complete rectal prolapse in adults.

Aim of Study: To assess the outcomes of laparoscopic ventral mesh rectopexy (LVMR) in the management of complete rectal prolapse regarding recurrence rate, operative complications, and post-operative improvement of urine incontinence and constipation.

Patients and Methods: This is a clinical trial conducted on 20 patients with rectal prolapse who underwent laparoscopic ventral mesh rectopexy admitted from General Surgery Out-patient Clinic in Fayoum University Hospital in the period from July 2015 to December 2017.

Results: Twenty patients, There was a male predominance, 15 male patients (75%) and 5 female patients (25%) The mean age of participants was 34.4 years. There was a significant improvement in constipation and inflammation and ulceration post-operatively. Recurrence occurred in one patient (5%).

Conclusion: The use of an anterior approach of laparoscopic rectopexy should be the first-line approach for cases with full-thickness RP. Because LVMR avoids the unnecessary repeated operations with all its psychological and physical impact on patients, the high success rate, minimal recurrence, and low complication rate for this procedure.

Key Words: Rectal prolapse – Laparoscopy – Rectopexy – Polypropylene Mesh.

Introduction

RECTAL prolapse (RP) is classified according to its severity into three major grades [1]; Mucosal prolapse is a disease in which the mucosal lining of the rectum protrudes through the anus. Internal prolapse, rectal intussusception, in which part of the rectal wall invaginates into the lumen of another part of the rectum. The third grade is complete prolapse of the rectum through the anus [2-4].

Correspondence to: Dr. Ayman M. Essawy, The Department of General Surgery, Faculty of Medicine, Fayoum University

Complete rectal prolapse (CRP) is circumferential herniation of all layers of the rectum through the anal sphincter [5,6]. CRP is a disabling disease affecting about 2.5 individuals per 100,000 population [7,8]. The exact etiology of rectal prolapse is unknown, however. Straight rectum, weakness of pelvic floor muscles and anal sphincter, and lack of ligamentous support of the rectum are considered anatomical predisposing factors for CRP [9]. A mass protruding from the anus is the main clinical feature of the CRP. At first, the prolapse occurs after defecation, but with time it may occur spontaneously upon standing or coughing. Incontinence is a frequent disabling symptom affecting about half of the patients with CRP [5,10,11]. The prolapsed rectum damages the rectal nerves and sphincters, which in turn, may lead to fecal incontinence not resolving after surgery [11].

Patients with CRP may suffer from a long history of constipation, which precedes the prolapse [12]. Weakness of the pelvic muscles by chronic straining may contribute to rectal prolapse. Surgical correction is the main treatment of CRP in adults [13,14]. The surgery aims to restore normal physiology and anatomy by correcting the prolapse [15,16]. It also improves bowel and sexual function. Many surgical procedures have been suggested to treat CRP. Available surgical treatment options include abdominal and perineal approaches [17,18]. Abdominal approaches either open or laparoscopic are better for young fit patients. On the other hand, the perineal approach is preferable for old patients who are unfit for abdominal procedures [19]. Laparoscopic correction of RP includes rectopexy and/or resection rectopexy. Laparoscopic ventral mesh rectopexy (LVMR) has been popularized in the past decade because of its benefits over alternative surgical options [20]. LVMR is associated with better anatomical results, fewer complications, less recurrence rate, and low mesh-related morbidity

[21,22]. The ventral approach avoids the circumferential mobilization which decreases the complications of rectal denervation [23].

Our aim in this study was to measure the success and suitability of the anterior approach of laparoscopic rectopexy for the treatment of complete rectal prolapse.

Patients and Methods

Study design:

The current clinical trial was conducted in general surgery outpatient clinic in Fayoum University Hospital in the period from 2015 to 2017 obtaining ethical approval from the local ethical committee and after taking fully informed consent from patients.

Patient selection and evaluation:

This study included 20 patients with rectal prolapse who underwent LVMR with polypropylene mesh.

Inclusion criteria:

- All patients have complete rectal prolapse without any other pathology by colonoscopy. All these patients were between 6 and 70 years old with no contraindication to laparoscopic surgery and those patients with American Society of Anesthesiologists (ASA) category I, II.
- Patients with failure of conservative management after at least 6 months.
- Patients with distressing symptoms such as rectal pain, bleeding, ulceration, and prolapse that require frequent manual reductions or show difficulty in reduction.
- Recurrent or persistent prolapse after previous trials of injection sclerotherapy or surgery.

Exclusion criteria:

- Patients who were younger than 6 years or older than 70 years.
- Cases of rectal polyps (till polyps are investigated and treated).
- RP following anorectal malformation procedures and Hirschsprung Disease repair.
- Patients with neurological causes for RP such as spina bifida, and meningomyelocele.
- Patients suffering from cystic fibrosis.

Data on age, gender, and preoperative baseline symptoms including constipation, urine incontinence were obtained. Operation time, intraoperative complications, immediate and late postoperative complications were assessed.

Preoperative assessment:

All patients underwent a comprehensive evaluation including a detailed history, full physical examination, barium enema, colonoscopy, electromyography, imaging, and routine preoperative investigations, such as full blood count, liver function tests, kidney function tests, and ECG for patients older than 60 years to assess the eligibility criteria and fitness for surgery.

All patients underwent bowel preparation by daily enema for 2 days preoperatively. They received 50mg/kg of ceftriaxone and 7.5mg/kg of metronidazole before surgery.

Operative procedure:

The procedure was performed under general anesthesia and the patients were in the supine position. Four ports were inserted, the first in the umbilicus for the camera, the second in the right midclavicular line for a grasper, the third was placed at the same position on the left side and the fourth was placed at the left anterior axillary line above the level of the umbilicus for grasping the rectum and keeping it in place throughout the procedure with the table in Trendelenburg position. Patients positioned in Trendelenburg position to expose the pelvic organs and the small intestine is retracted cephalad. Hysteropexy may be performed as needed for exposure. The rectosigmoid is retracted toward the spleen to expose the peritoneum. The right ureter is identified along the right pelvic sidewall. The right-side peritoneum is then incised at the level of the sacral promontory and the peritoneal dissection continues downward in the mid-point between the rectum and sidewall to the level of the pelvic floor. Dissection is carried down in the anterior space via Denonvilliers fascia to the rectovaginal space. In men, the dissection in the recto-vesical pouch is carried to the apex of the prostate but the lateral dissection around the seminal vesicles is avoided. In some cases, the hernia sac can be redundant and/or associated with an enterocele. In these cases, the peritoneal sac is resected.

Posterior and lateral dissection is avoided. Once the anterior space is mobilized, polypropylene mesh is secured to the anterior aspect of the rectum and The proximal end of the mesh is anchored to the sacral promontory with sutures or tacks using 0 Ethibond suture, taking care to avoid full-thickness rectal bites, Two or Three polypropylene sutures (3/0) were used to fix the seromuscular wall of the lowermost part of the rectum. This elevates the anterior wall without any traction on the rectum. The posterior vaginal fornix is lifted and sutured to the mesh (anteriorly), aiding in the

repair of the rectocele, as well as prolapse. The proximal end of the mesh is anchored to the sacral promontory with sutures or tacks. The pelvic peritoneum is then approximated to extraperitonealize the mesh closed by absorbable sutures and the port site wounds were closed using subcuticular sutures.

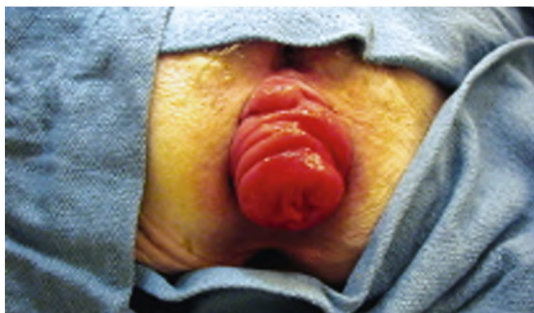

Fig. (1): Shows patient with complete rectal prolapse.

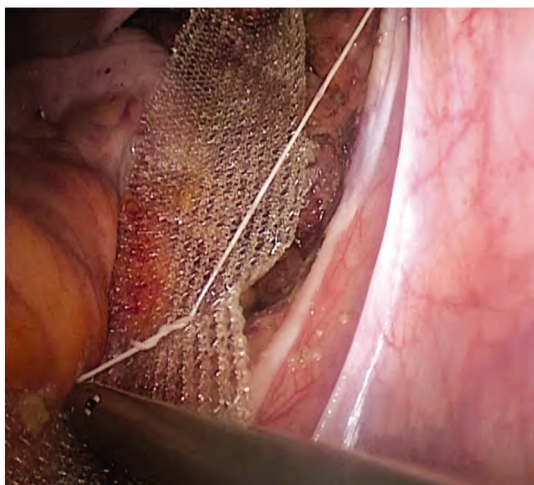


Fig. (2): Shows fixation of mesh to the rectum and sacral promontory.

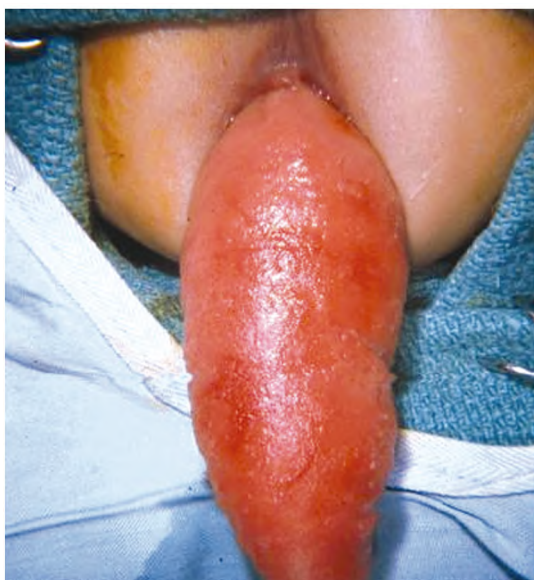

Fig. (3): Showing severe rectal prolapse with clinically significant edema and mucosal ulceration.

Follow-up:

Stool softeners were used for one month after operation along with instructions to avoid constipation, lifting heavy objects, straining, doing heavy exercise for six weeks, having sexual intercourse for four weeks. Follow-up duration ranged from 6-12 months.

Statistical analysis:

Data were presented as mean ± standard deviation, number, and percentages. Statistical analysis was performed using MedCalc© version 12.5 (MedCalc© Software bvba, Ostend, Belgium) and Microsoft© Excel© 2010 (Microsoft© Corp., Redmond, Washington, USA).

Results

Demographic and clinical characteristics:

The study included twenty patients with CRP who underwent LVMR. The patients were admitted from the outpatient clinic in Fayoum University Hospital in the period from 2015 to 2017. The mean age of participants was 34.4±19.8 (range: 8-70) years. There was male predominance. They were 15 male patients (75%) and 5 female patients (25%). The baseline preoperative symptoms were constipation in 35% of patients, urine incontinence in 5% of patients, inflammation and ulceration by colonoscopy in 30% of patients. Baseline demographic data are illustrated in detail in Table (1).

Table (1): Baseline demographic data of 20 patients with complete rectal prolapse.

Number (%)	20 (100%)
Age (mean ±SD)	34.4±19.8
Sex (male: female)	15:5
Constipation n (%)	7 (35%)
Urine incontinence n (%)	1 (5%)
Inflammation and Ulceration n (%)	6 (30%)
Previous surgery rectal prolapse n (%)	4 (20%)
Barium enema abnormalities n (%)	0 (0%)
Conversion to open surgery n (%)	1 (5%)
Average operating time (min)	75 (60-90)
Follow up duration range (month)	6:12
Average hospital stay (days)	3 (1-5)

n = Number. SD = Standard deviation. min = Minute.

Primary outcomes:

1- Constipation:

Seven patients were constipated preoperatively (35%). There was a significant postoperative improvement of patients with constipation. All patients reported an absence of constipation (100%) after the operation.

2- Urine incontinence:

Only one patient complained of urinary incontinence before operation. There was no effect on the continence of patients. After the operation, there was one patient still complaining of urinary incontinence.

3- Inflammation and ulceration by colonoscopy:

There was a significant improvement of inflammation and ulceration after the operation. All patients showed complete healing of the colon after our approach.

4- Operative complications:

There was no bowel injury, nerve injury, major blood loss, or mesh erosion that occurred during the operation. Only one case (5%) was converted to open rectopexy as dissection was lateral and pelvic vessels were exposed. Another patient (5%) reported postoperative pain on defecation resulting from an acquired anal fissure during preoperative preparation and it was managed conservatively. Another patient (5%) complained of perianal maceration from severe diarrhea. A third patient had prolonged postoperative ileus and initiated feeding on the fourth postoperative day. This patient was discharged home on the fifth day and returned to the hospital with feeding intolerance.

5- Recurrence:

Recurrence of rectal prolapse after our procedure occurred in one patient (5%) that was managed with open rectopexy.

Discussion

All patients presented with RP during the period of the study. Twenty patients who had complete persistent rectal prolapse or recurring after previous interventions were subjected to an anterior approach of laparoscopic rectopexy. Male predominance was noted in our study, which was also noted in Potter et al., Flum et al., Laituri et al., and Chan et al., [24-27]. In pediatrics rectal prolapse affects equally males and females. The disease is much more common in underdeveloped countries, with common causes including parasitic disease, malnutrition, and diarrheal illness [14].

Twelve patients had no associated comorbidities. Patients tend to strain vigorously against closed sphincters, leading eventually to prolapse. Some authors considered that prolongation of the conservative treatment time is inappropriate because it is distressing for patients with unlikelihood of response. Therefore, early surgical intervention was considered more appropriate in such cases

[28,29]. In the study by Potter et al., 47% of patients had no predisposing factors [24]. Also in Flum et al., 62% of patients had no predisposing factors [25]. However, meticulous history taking and thorough re-examination were done to pick up any predisposing factor that would have been missed. Other treatable predisposing factors such as constipation, diarrhea, and malnutrition were managed by stool softeners and diet modification.

Laituri et al., in 2010 [26] reported that extensive evaluation is not necessary in most uncomplicated cases as evaluation of patients with RP is relatively straightforward. However, we had baseline investigations for all patients which were stool culture, plain X-ray abdomen, barium enema, and colonoscopy to assess the presence of any other pathologies and the fitness of patients. In 2010, Potter et al., [24] used colonoscopy or barium enema before operative intervention for evaluation of rectum.

Ismail et al., [30] in their study used plain radiographs, barium enema, proctoscopy, colonoscopy, and pre and post-operative EMG. We reserved the use of colonoscopy for adult cases of significant bleeding per rectum or abnormalities detected on barium enemas. Similarly, EMG use was conserved for cases with the significantly diminished anal tone, as Pelvic floor weakness, which is usually seen in adults and rarely seen in children [31].

Our operative time ranged from 60-90 minutes with a mean of 75 minutes. Potter et al., [24] had a range from 28-117 minutes with a mean of 72 minutes. Ismail et al., [30] had a range from 50-70 minutes with a mean of 60 minutes. Abdominal procedure via the laparoscopic approach is now the recommended approach in all cases. The laparoscopic sigmoid resection with or without rectopexy reported a recurrence rate of 2% to 5% [32]. Generally, in mesh rectopexy, there is a circumferential mobilization of the rectum to the pelvic floor with a ventral or a posterior application of the mesh. The circumferential mobilization of the rectum usually damages the autonomic supply of the rectum, which in turn disturbs rectosigmoid motility leading to de novo or worsening of existing constipation [33]. Other techniques that performed complete mobilization of the rectum, were found to be unnecessary as good results were obtained without the need for complete mobilization [34].

In 2006, D'Hoore et al., [22] described "nerve-sparing ventral rectopexy" as a procedure of choice for rectal prolapse. The uniqueness of laparoscopic ventral rectopexy is that it avoids any posterolateral dissection of the rectum thus leaving the autonomic

innervation intact. Currently, this technique has gained widespread acceptance and is considered the standard of care for the management of pelvic organ prolapse [35]. The combined benefits of the laparoscopic approach and anterior approach of rectopexy have made the procedure safe and effective with minimal post-operative functional disturbance.

Several studies reported a recurrence rate of about 5% following LVMR. Most recurrences occur within the first 2-3 years [22,36]. The risk of recurrence is similar to that reported for other abdominal procedures 2% to 9% [37]. The overall Recurrence, in our study, is one out of twenty patients 5% that is being managed with open rectopexy and improved on follow-up. LVMR is associated with a lower incidence of recent-onset constipation. Besides, it shows a great improvement in pre-existing constipation as compared with posterior rectal dissection.

Three randomized trials have shown an improvement in constipation by avoiding lateral and posterior dissection [38-40].

Post-operative dyschezia and constipation were reported in many case series [30,41]. These post-operative symptoms weren't encountered in our study, which is attributed to the avoidance of retro rectal dissection.

One can argue that the use of an anterior approach of laparoscopic rectopexy is the first-line approach for cases with full-thickness RP. Because LVMR avoids the unnecessary repeated operations with all its psychological and physical impact on patients, the high success rate, minimal recurrence, and low complication rate for this procedure.

Study limitations were the relatively small number of patients, but this could be attributed to the characteristics of the disease in children and the fact that a big number of patients resolve spontaneously, which is the same limitation in most studies dealing with the RP.

The other limitation is the relatively short period of follow-up. Subsequent studies with a longer follow-up period would be useful in accessing the success rate of the LVMR.

From the obtained results, we found that the anterior approach of laparoscopic rectopexy is a simple, minimally invasive technique, with reasonable operative time and minimal immediate post-operative morbidities.

References

- 1- JONES O.M., CUNNINGHAM C. and LINDSEY I.: The assessment and management of rectal prolapse, rectal intussusception, rectocele, and enterocele in adults. *BMJ*, 2011.
- 2- TSUNODA A., TAKAHASHI T., YAGI Y. and KUSANAGI H.: Rectal intussusception and external rectal prolapse are common at proctography in patients with mucus discharge. *J. Anus, Rectum, Colon.*, 2018.
- 3- BLAKER K. and ANANDAM J.L.: Functional Disorders: Rectoanal Intussusception. *Clin. Colon. Rectal Surg.*, 2017.
- 4- TSIAOISSIS J., CHRYSOS E., ATHANASAKIS E., PECHLIVANIDES G., TZORTZINIS A., ZORAS O., et al.: Rectoanal intussusception: Presentation of the disorder and late results of resection rectopexy. *Dis. Colon. Rectum.*, 2005.
- 5- FELT-BERSMA R.J.F., STELLA M.T.E. and CUESTA M.A.: Rectal Prolapse, Rectal Intussusception, Rectocele, Solitary Rectal Ulcer Syndrome, and Enterocele. *Gastroenterology Clinics of North America*, 2008.
- 6- FELT-BERSMA R.J.F. and CUESTA M.A.: Rectal prolapse, rectal intussusception, rectocele, and solitary rectal ulcer syndrome. *Gastroenterol. Clin. North Am.*, 2001.
- 7- KAIRALUOMA M.V. and KELLOKUMPU I.H.: Epidemiologic aspects of complete rectal prolapse. *Scand J. Surg.*, 2005.
- 8- M.V. K and I.H. K.: Epidemiologic aspects of complete rectal prolapse. *Scand J. Surg.*, 2005.
- 9- VOGLER S.A.: Rectal Prolapse. *Dis. Colon. Rectum.*, 2017.
- 10- JACOBS L.K., YU JU LIN and ORKIN B.A.: The best operation for rectal prolapse. *Surg. Clin. North Am.*, 1997.
- 11- ROIG J.V., BUCH E., ALÓS R., SOLANA A., FERNÁNDEZ C., VILLOSLADA C., et al.: Anorectal function in patients with complete rectal prolapse. Differences between continent and incontinent individuals. *Rev. Esp. Enfermedades Dig.*, 1998.
- 12- YOON S.G.: Rectal prolapse: Review according to the personal experience. *Journal of the Korean Society of Coloproctology*, 2011.
- 13- CANNON J.A.: Evaluation, Diagnosis, and Medical Management of Rectal Prolapse. *Clin. Colon. Rectal Surg.*, 2017.
- 14- RENTEA R.M. and ST PETER S.D.: Pediatric Rectal Prolapse. *Clin. Colon. Rectal Surg.*, 2018.
- 15- PERIER P., HOHENBERGER W., LAKEW F. and DIEGELER A.: Prolapse of the posterior leaflet: Resect or respect. *Ann. Cardiothorac. Surg.*, 2015.
- 16- ANTUNES M.J.: Revisiting posterior mitral leaflet prolapse: Resect, respect, or resect with respect? *Journal of Thoracic and Cardiovascular Surgery*, 2018.
- 17- SAADAI P., TRAPPEY A.F. and LANGER J.L.: Surgical Management of Rectal Prolapse in Infants and Children. *European Journal of Pediatric Surgery*, 2020.
- 18- MARDERSTEIN E.L. and DELANEY C.P.: Surgical management of rectal prolapse. *Nature Clinical Practice Gastroenterology and Hepatology*, 2007.

- 19- MUSTAIN W.C., DAVENPORT D.L., PARCELLS J.P., VARGAS H.D. and HOURIGAN J.S.: Abdominal versus perineal approach for treatment of rectal prolapse: Comparable safety in a propensity-matched cohort. *Am. Surg.*, 2013.
- 20- VAN IERSEL J.J., PAULIDES T.J.C., VERHEIJEN P.M., LUMLEY J.W., BROEDERS I.A.M.J. and CONSTEN E.C.J.: Current status of laparoscopic and robotic ventral mesh rectopexy for external and internal rectal prolapsed. *World Journal of Gastroenterology*, 2016.
- 21- D'HOORE A., CADONI R. and PENNINCKX F.: Long-term outcome of laparoscopic ventral rectopexy for total rectal prolapse. *Br. J. Surg.*, 2004.
- 22- D'HOORE A. and PENNINCKX F.: Laparoscopic ventral recto(colpo)pey for rectal prolapse: Surgical technique and outcome for 109 patients. *Surg. Endosc. Other Interv. Tech.*, 2006.
- 23- FAUCHERON J.L., TRILLING B., GIRARD E., SAGE P.Y., BARBOIS S. and RECHE F.: Anterior rectopexy for full-thickness rectal prolapse: Technical and functional results. *World Journal of Gastroenterology*, 2015.
- 24- POTTER D.D., BRUNY J.L., ALLSHOUSE M.J., NARKEWICZ M.R., SODEN J.S. and PARTRICK D.A.: Laparoscopic suture rectopexy for full-thickness anorectal prolapse in children: An effective outpatient procedure. *J. Pediatr. Surg.*, 2010.
- 25- FLUM A.S., GOLLADAY E.S. and TEITELBAUM D.H.: Recurrent rectal prolapse following primary surgical treatment. *Pediatr. Surg. Int.*, 2010.
- 26- LAITURI C.A., GAREY C.L., FRASER J.D., AGUAYO P., OSTLIE D.J., ST. PETER S.D., et al.: 15-Year experience in the treatment of rectal prolapse in children. *J. Pediatr. Surg.*, 2010.
- 27- M.A.B. F and S.E.: Outcome of submucosal injection of different sclerosing materials for rectal prolapse in children. *Pediatric Surgery International*, 2004.
- 28- DREZNIK Z., VISHNE T.H., KRISTT D., ALPER D. and RAMADAN E.: Rectal prolapse: A possibly underrecognized complication of anorexia nervosa amenable to surgical correction. *Int. J. Psychiatry Med.*, 2001.
- 29- DASELER E.H.: Rectal prolapse in the mentally retarded. *Dis. Colon. Rectum.*, 1967.
- 30- SHALABY R., ISMAIL M., ABDELAZIZ M., IBRAHEM R., HEFNY K., YEHYA A., et al.: Laparoscopic mesh rectopexy for complete rectal prolapse in children: A new simplified technique. *Pediatr. Surg. Int.*, 2010.
- 31- SHAH A., PARIKH D., JAWAHEER G. and GORNALL P.: Persistent rectal prolapse in children: Sclerotherapy and surgical management. *Pediatric Surgery International*, 2005.
- 32- FLEMING F.J., KIM M.J., GUNZLER D., MESSING S., MONSON J.R.T. and SPERANZA J.R.: It's the procedure not the patient: The operative approach is independently associated with an increased risk of complications after rectal prolapse repair. *Color Dis.*, 2012.
- 33- TOU S., BROWN S.R. and NELSON R.L.: Surgery for complete (full-thickness) rectal prolapse in adults. *Cochrane Database of Systematic Reviews*, 2015.
- 34- PURI B.: Rectal prolapse in children: Laparoscopic suture rectopexy is a suitable alternative. *J. Indian Assoc. Pediatr. Surg.*, 2010.
- 35- WIJFFELS N.A., COLLINSON R., CUNNINGHAM C., LINDSEY I.: What is the natural history of internal rectal prolapse? *Color Dis.*, 2010.
- 36- FORMIJNE JONKERS H.A., POIERRIÉ N., DRAAISMA W.A., BROEDERS I.A.M.J. and CONSTEN E.C.J.: Laparoscopic ventral rectopexy for rectal prolapse and symptomatic rectocele: An analysis of 245 consecutive patients. *Color Dis.*, 2013.
- 37- VARMA M., RAFFERTY J. and BUIE W.D.: Practice parameters for the management of rectal prolapse. *Dis. Colon. Rectum.*, 2011.
- 38- MOLLEN R.M.H.G., KUIJPERS J.H.C. and VAN HOEK F.: Effects of rectal mobilization and lateral ligaments division on colonic and anorectal function. *Dis. Colon. Rectum.*, 2000.
- 39- SELVAGGI F., DI CARLO E.S., SILVESTRI A. and SEOW-CHOENY F.: Prospective randomized study of radical versus four piles haemorrhoidectomy for symptomatic large circumferential prolapsed piles. *British Journal of Surgery*, 1995.
- 40- SPEAKMAN C.T.M., MADDEN M.V., NICHOLLS R.J. and KAMM M.A.: Lateral ligament division during rectopexy causes constipation but prevents recurrence: Results of a prospective randomized study. *Br. J. Surg.*, 1991.
- 41- KOIVUSALO A., PAKARINEN M. and RINTALA R.: Laparoscopic suture rectopexy in the treatment of persisting rectal prolapse in children: A preliminary report. *Surg. Endosc. Other Interv. Tech.*, 2006.

استخدام المنظار فى تركيب شبكة لتثبيت المستقيم للمرضى الذين يعانون من سقوط شرجى كلى

إن السقوط الشرجى شائع نسبياً فى الأطفال وكبرى السن، ففى العديد من الحالات يكون من الصعب التوصل للسبب المؤدى للسقوط الشرجى والتليف الكيسى يعتبر من أهم أسباب المرضى فى المجتمع الغربى إلى جانب الإمساك ومشاكل التبرز. تختلف الأسباب فى الدول النامية التى يعتبر سوء التغذية، الإسهال، التعنية والطفليات من أهم أسباب المرض بها.

تقييم المرضى الذين يعانون من السقوط الشرجى بسيط وفى أغلب الحالات يتم الاعتماد على التاريخ المرضى لتعذر رؤية السقوط الشرجى فى العيادات أحياناً.

علاج هؤلاء المرضى يشمل إصلاح المسببات إن وجدت مثل الإمساك والإسهال أو سوء التغذية، كما ينصح بعدم إجراء تدخل جراحى إلا بعد عمل علاج تحفظى ولكن قد تقصر المدة إذا كانت درجة السقوط الشرجى شديدة أو إذا كانت تحتاج إلى إرجاها باليد أو وجود نزيف شرجى وتبعيات ذلك من التوتر الذى يصيب الأهل والمريض.

هدف هذه الرسالة هو تقييم استخدام المنظار فى تثبيت المستقيم للمرضى الذين يعانون من سقوط شرجى كلى. حيث يتم تثبيت الجزء الأعلى من المستقيم بعد فتح الجزء الخلفى من البريتون وتسليك أمام المستقيم، مع الامتداد الحرقفى عن طريق شبكة البولى بربولين بغرز غير قابلة للامتصاص ثم اغلاق البريتون عليها عن طريق غرز قابلة لامتصاص.

إن تقنية الاصلاح الأمامى بالمنظار الجراحى للسقوط الشرجى الكلى تتسم بالبساطة وتتمتع بنسبة نجاح مرتفعة فى حالات السقوط الشرجى الكلى وبها مميزات قصر فترة النقاهة والإقامة بالمستشفى بالإضافة إلى وجود ندبات لا تذكر بالمقارنة بحالات الجراحة من البطن، حيث أن معدل نجاحها بلغ ٩٥% فى الحالات التى تم إجراء تثبيت المستقيم بالمنظار لها.

فحينما تتوافر الخبرات من الممكن إجراء هذا النوع من العمليات كجراحة اليوم الواحد ولهذا أصبحت تقنية الاصلاح الأمامى بالمنظار الجراحى للسقوط الشرجى الكامل اختيارنا الأول لحالات السقوط الشرجى الكلى وهذا لا ينفى الاحتياج لفترة متابعة أطول للحالات لتبين حدوث ارتجاع للسقوط الشرجى من عدمه على المدى البعيد.

أن نسب النجاح المرتفعة المنسوبة إلى التقنيات الأخرى فى الأبحاث نستنتج منها أنه إذا تم دمج كل من اختيار التقنية الملائمة للحالة بجانب تمرس الجراح بالتقنية فذلك يؤدى إلى أعلى معدلات النجاح، وأنه إلى وقتنا هذا لا توجد تقنية واحدة تعد الأمثل لكل الحالات.